

# Benign Oral Cavity and Oropharyngeal Lesions: A Histopathological Review and Their Relationship to HPV Infection

Afiati<sup>1\*</sup>, Khoirul Anam<sup>2</sup>

<sup>1</sup>Department of Anatomical Pathology, Faculty of Medicine, Syarif Hidayatullah State Islamic University Jakarta, Indonesia

<sup>2</sup>Department of Otolaryngology Head and Neck Surgery, Faculty of Medicine, Syarif Hidayatullah State Islamic University Jakarta, Indonesia

\*Corresponding author:

**E-mail:** [afiati@uinjkt.ac.id](mailto:afiati@uinjkt.ac.id)

---

## Abstract.

*Background:* Human Papillomavirus (HPV) is one of the causes of benign lesions in the oral cavity and oropharynx. The most common lesions include squamous cell papilloma, condyloma acuminatum, verruca vulgaris, and multifocal epithelial hyperplasia (MFEH). Although benign, these four lesions have overlapping clinical and histopathological characteristics, often making diagnosis difficult. The purpose of this literature review is to review the clinical characteristics, histopathology, differential diagnosis, management, and prognosis of benign lesions of the oral cavity and oropharynx associated with HPV infection. *Methods:* This article was compiled using a narrative literature review method. The literature search was conducted through PubMed, Google Scholar, and ScienceDirect using keywords related to HPV and benign lesions of the oral cavity. Literature published in Indonesian and English between 2017 and 2025 was selected based on relevance to the anatomy, histology, epidemiology, etiology, clinical manifestations, macroscopic and microscopic features, differential diagnosis, management, and prognosis of benign lesions of the oral cavity and oropharynx associated with HPV. *Results:* Benign lesions of the oral cavity and oropharynx associated with HPV consist of squamous cell papilloma, condyloma acuminatum, verruca vulgaris, and MFEH. Most lesions are associated with low-risk HPV infection, especially types 6 and 11, with a predilection for the labial mucosa, tongue, buccal mucosa, and palate. The clinical presentation of lesions associated with HPV is generally an exophytic growth with a papillary or verrucous surface. Histopathologically, all lesions showed squamous epithelial proliferation accompanied by koilocytes as a marker of HPV cytopathic effects, while mitotic bodies are a characteristic feature and are more frequently found in MFEH. *Diagnosis* is established through correlation between history taking, clinical examination, and histopathological evaluation to differentiate benign lesions from potentially malignant lesions. Simple excision is the mainstay of therapy with a generally good prognosis, although condyloma acuminatum has a tendency to recur. *Conclusion:* Diagnosis of benign lesions of the oral cavity and oropharynx associated with HPV requires integration of clinical characteristics, histopathology, and, if necessary, molecular examination. Understanding the differences in the characteristics of each lesion is important to improve diagnostic accuracy, determine appropriate management, and prevent misdiagnosis of malignant lesions.

**Keywords:** Human Papillomavirus, oral cavity, oropharynx, squamous cell papilloma, condyloma acuminatum, verruca vulgaris and multifocal epithelial hyperplasia.

---

## I. INTRODUCTION

Various diseases can be found in the oral cavity and oropharynx, one of which is related to the Human Papillomavirus (HPV). HPV is a virus that infects the mucosal epithelium and skin and plays a role in the formation of various benign and malignant lesions in the upper aerodigestive tract (Jonathan, 2018). Globally, the prevalence of lesions in the oral cavity and oropharynx associated with HPV infection continues to increase, with reported prevalence rates varying between 1% and 50% in the general population and the incidence of benign lesions around 3% (Nishanth et al., 2020; Magalhães et al., 2021). Benign lesions in the oral cavity and oropharynx associated with HPV include verruca vulgaris, condyloma acuminatum, squamous papilloma, and focal epithelial hyperplasia or Heck disease (Jonathan, 2018; Magalhães et al., 2021; ElNaggar, 2017).

Based on their etiology, most benign HPV-related oral and oropharyngeal lesions are caused by low-risk HPV types, particularly types 6 and 11, which are reported to be involved in approximately 41.8% of benign papillary lesions (Mariana et al., 2019; Syrjänen & Syrjänen, 2021). The incidence of these lesions is relatively equal in men and women, with the age range between 11 and 60 years, with the highest incidence in the fourth and fifth decades of life (ElNaggar, 2017; Mariana et al., 2019). The clinical manifestations of

these lesions vary widely, and can include pedunculated or sessile lesions that grow solitary or multiple, with colors resembling normal mucosa, ranging from whitish to pink. Lesions can be symptomatic or asymptomatic depending on the size and location of the lesion (ElNaggar, 2017; Betz, 2019).

Surgical excision is the primary treatment option for most benign HPV-related lesions because it yields good results and allows for histopathological examination to establish a definitive diagnosis (ElNaggar, 2017; Betz, 2019). Therefore, a comprehensive understanding of benign HPV-related oral and oropharyngeal lesions is essential to support appropriate diagnosis and management. This literature review aims to discuss the anatomy and histology of the oral cavity and oropharynx, including the definition, epidemiology, etiology, clinical manifestations, histopathological features, differential diagnosis, management, and prognosis of each benign lesion associated with HPV infection (Jonathan, 2018; Eroschenko, 2021; Betz, 2019; Prabhu, 2023).

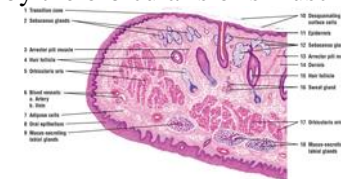
## II. METHODOLOGY

This article was compiled using a narrative literature review method to review benign lesions of the oral cavity and oropharynx associated with Human Papillomavirus (HPV) infection. Literature was obtained through searches of the PubMed, Google Scholar, and ScienceDirect databases using the keywords "human papillomavirus", "oral HPV lesions", "benign oral lesions", "squamous cell papilloma", "condyloma acuminatum", "verruca vulgaris", and "multifocal epithelial hyperplasia". Literature published between 2017 and 2025 in English and Indonesian was considered. Inclusion criteria included research articles, review articles, case reports, reference books, and the WHO classification that discussed benign HPV-related oral and oropharyngeal lesions, particularly regarding clinical characteristics, histopathology, differential diagnosis, management, and prognosis. Literature that was irrelevant to the topic or exclusively discussed malignant lesions was excluded. All literature that met the criteria was critically reviewed and narratively synthesized to compile a review of the anatomy and histology of the oral cavity and oropharynx, characteristics of benign HPV-related lesions, macroscopic and microscopic features, differential diagnosis, management, and prognosis.

## III. RESULTS AND DISCUSSIONS

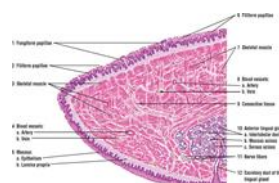
### Anatomy and Histology

The oral cavity and oropharynx are part of the digestive tract and include the lips, floor of the mouth, tongue, buccal mucosa, gingiva, retromolar trigone, hard palate, tonsils, soft palate, and pharyngeal wall. The oral and oropharyngeal mucosa is generally lined with non-keratinized stratified squamous epithelium that serves a protective function, while keratinization is found on the gingiva, hard palate, and dorsal surface of the tongue. The lamina propria is composed of loose connective tissue and seromucous glands from minor salivary glands (Jonathan, 2018; Eroschenko, 2021). The lips are lined with keratinized stratified squamous epithelium that transitions to non-keratinized stratified squamous epithelium at the free edge, contain mucus-producing labial glands, and are supported by the orbicularis oris muscle (Eroschenko, 2021).

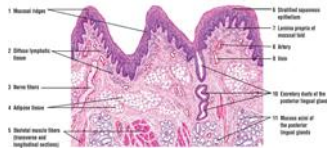

**Fig. 1. Histology of the lip (Eroschenko, 2021)**

The tongue is a muscular organ that plays a role in speech, chewing, and swallowing. The dorsal surface of the tongue is divided into an anterior two-thirds and a posterior one-third, separated by the terminal sulcus. The epithelium on the dorsal surface is stratified squamous epithelium with partial keratinization, while the ventral surface is lined with stratified squamous epithelium without keratinization. The dorsal surface of the tongue has four types of papillae: filiform, fungiform, circumvallate, and foliate papillae (Eroschenko, 2021).

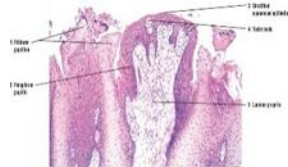

**Fig. 2. Histology of the anterior tongue (Eroschenko, 2021)**

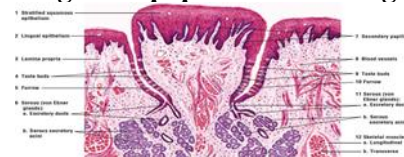

**Fig. 3. Posterior histology of the tongue (Eroschenko, 2021)**

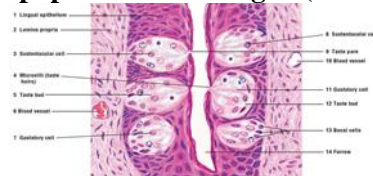Filiform papillae are the most numerous papillae on the dorsal surface of the tongue, undergo keratinization, and do not contain taste buds. Fungiform, circumvallate, and foliate papillae contain taste buds, with approximately 8–12 circumvallate papillae in the posterior region of the tongue and associated with serous glands (von Ebner), which function to dissolve taste substances. Taste buds are also found in the soft palate, pharynx, and epiglottis and are composed of gustatory cells, sustentacular cells, and basal cells (Eroschenko, 2021).



**Fig. 4. Filiform papillae and fungiform papillae on the tongue (Eroschenko, 2021)**

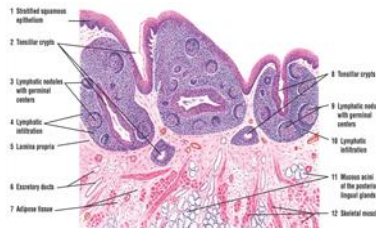

**Fig. 5. Circumvallate papillae on the tongue (Eroschenko, 2021)**



**Fig. 6. Taste buds on the tongue (Eroschenko, 2021)**

The tonsils are collections of lymphoid tissue in the oropharynx consisting of the palatine tonsils, pharyngeal tonsils, and lingual tonsils. The palatine and lingual tonsils are lined with non-keratinized stratified squamous epithelium, while the pharyngeal tonsils are lined with pseudostratified ciliated epithelium. The palatine tonsils have numerous crypts and are separated from the surrounding tissue by a fibrocollagenous capsule, while the lamina propria of the tonsils contains numerous lymphatic nodules with germinal centers.(Eroschenko, 2021).



**Fig. 7. Lingual tonsils (Eroschenko, 2021)**

## Benign Oral Cavity and Oropharyngeal Lesions Associated with HPV

### a. Classification

Based on the WHO Classification of Head and Neck Tumours (2017), benign lesions of the oral cavity and oropharynx associated with HPV include squamous cell papilloma, condyloma acuminatum, verruca vulgaris, and multifocal epithelial hyperplasia (MFEH). The Ackerman classification is similar, referring to focal epithelial hyperplasia (Heck disease) as MFEH (Jonathan, 2018; ElNaggar, 2017).

### b. Definition

Squamous cell papilloma is a benign hyperplastic exophytic lesion with a verrucous morphology resembling cauliflower. Condyloma acuminatum is a benign papillary lesion caused by HPV. Verruca vulgaris is a benign hyperplastic lesion caused by HPV with a similar morphology, while MFEH is a benign squamous epithelial proliferation of the oral mucosa associated with HPV infection (Jonathan, 2018; ElNaggar, 2017).

### c. Epidemiology

Squamous cell papilloma can occur at any age with an equal distribution between men and women, especially in the third to fifth decades (EINaggar, 2017; Betz, 2019). Condyloma acuminatum is more common in young adults and men, but can also occur in children due to sexual abuse or in immunocompromised patients (EINaggar, 2017; Chaturvedi & Chaturvedi, 2020). Verruca vulgaris generally occurs in the third to fourth decades, more often in men, and approximately 10% of cases are found in children and young adults due to autoinoculation (EINaggar, 2017; Betz, 2019). MFEH is more common in children and adolescents with a female predominance (5:1) (EINaggar, 2017).

#### d. Etiology

Most squamous cell papillomas and condyloma acuminatum are caused by HPV types 6 and 11 (EINaggar, 2017; Betz, 2019; Andrade et al., 2019). Verruca vulgaris is primarily caused by HPV types 2, 4, 40, and 57, with autoinoculation being the most common transmission mechanism (EINaggar, 2017; Betz, 2019; Adel et al., 2020). MFEH is associated with HPV types 1, 6, 11, 13, 16, 18, 32, and 55, with a higher risk in patients with HIV, low socioeconomic status, malnutrition, and densely populated environments (EINaggar, 2017; Betz, 2019; Agho et al., 2020).

#### e. Location

Squamous cell papilloma is most commonly found on the soft palate, tongue, lips, and gingiva, while condyloma acuminatum primarily affects the labial mucosa, buccal mucosa, soft palate, frenulum, and floor of the mouth. Verruca vulgaris is commonly found on the labial mucosa, palate, anterior tongue, and gingiva, while MFEH most commonly affects the lips, buccal mucosa, and tongue (EINaggar, 2017; Betz, 2019; Chaturvedi & Chaturvedi, 2020; Andrade et al., 2019; Adel et al., 2020; Agho et al., 2020).


#### f. Clinical Manifestations

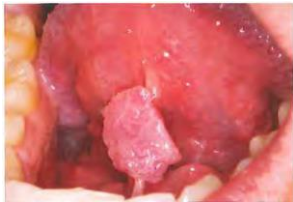


All four lesions are generally asymptomatic and exhibit exophytic growth. Squamous cell papilloma is typically a solitary, pedunculated or sessile lesion with a papillary or verrucous surface measuring approximately 0.5 cm, while multiple lesions can be found in HIV patients (EINaggar, 2017; Betz, 2019; Andrade et al., 2019; Aldhafeeri et al., 2020). Condyloma acuminatum can appear 1–3 months after infection as a solitary or multiple pink lesions of larger size ( $\pm 15$  mm) and is often associated with anogenital lesions (EINaggar, 2017; Chaturvedi & Chaturvedi, 2020). Verruca vulgaris is a white, rough-surfaced or papillary lesion measuring  $< 5$  mm that can appear solitary or multiple (EINaggar, 2017; Adel et al., 2020). MFEH is characterized by multiple papules the same color as the mucosa, measuring 5–10 mm, which can coalesce to form plaques (EINaggar, 2017; Agho et al., 2020).

#### g. Clinical Characteristics of Benign Oral Cavity and Oropharyngeal Lesions Associated with HPV

The macroscopic characteristics of benign lesions of the oral cavity and oropharynx associated with HPV can be seen in Table 1. In general, all lesions show exophytic growth with variations in papillary or verrucous forms. Squamous cell papilloma is generally a small solitary lesion resembling a cauliflower, condyloma acuminatum is a pink papillary mass with a larger size, verruca vulgaris is a white lesion with a rough surface, while MFEH is multiple mucosa-colored papules (EINaggar, 2017; Chaturvedi & Chaturvedi, 2020; Andrade et al., 2019; Adel et al., 2020; Agho et al., 2020).

**Table 1. Comparison of macroscopic features of benign lesions of the oral cavity and oropharynx associated with HPV**


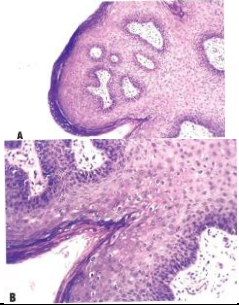
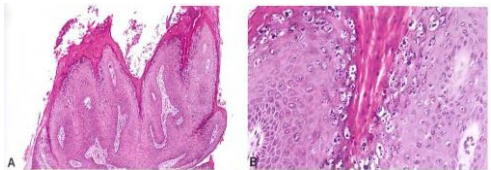
Lesion	Macroscopic view	Picture
<i>Squamous cell papilloma</i>	Sessile or pedunculated lesions, solitary, well-defined, oval or dome-shaped, verrucous surface resembling cauliflower, white to pink in color, size $\pm 0.5$ cm.	

<i>Condyloma acuminatum</i>	Sessile, solitary or multiple masses, exophytic growth, smooth, nodular surface, pink to red in color, ±15 mm in size. <sup>4</sup>	
<i>Verruca vulgaris</i>	Exophytic lesions, generally sessile, white, rough surface with finger-like projections, irregular borders, size <5 mm. <sup>4, 11</sup>	
<i>Multifocal epithelial hyperplasia</i>	Multiple, soft, mucosal-colored papules or papulonodular lesions, 5–10 mm in size, may coalesce to form plaques. <sup>4, 12</sup>	

**h. Histopathological Characteristics of Benign Oral Cavity and Oropharyngeal Lesions Associated with HPV**

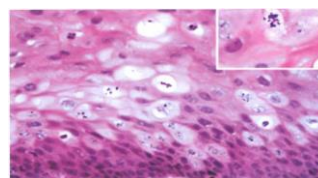
The histopathological characteristics of each lesion can be seen in Table 2. All lesions showed squamous epithelial proliferation with distinct characteristics. Koilocytes are a typical finding in HPV-related lesions, while mitosoid bodies are a specific characteristic of MFEH (EINaggar, 2017; Focchi et al., 2020).

**Table 2. Comparison of microscopic images of benign lesions of the oral cavity and oropharynx associated with HPV**

Lesion	Microscopic image	Picture
<i>Squamous cell papilloma</i>	Papillary proliferation of stratified squamous epithelium with finger-like projections, fibrovascular core, variable hyperkeratosis, edematous/hyalinized stroma, koilocytes and rare mitoses.	
<i>Condyloma acuminatum</i>	Papillomatosis, acanthosis, extensive fibrovascular core, wide base, clear koilocytes, mitosis and apoptosis can be found, stroma rich in blood vessels and inflammatory cells.	
<i>Verruca vulgaris</i>	Hyperkeratosis, elongated and fused rete ridges, prominent keratohyaline granules, koilocytic changes in the superficial layers.	

**Multifocal epithelial hyperplasia**

Mild hyperkeratosis, prominent acanthosis with normal epithelial cell maturation, koilocytosis, and characteristic mitosoid bodies composed of karyorrhectic nuclei resembling mitotic figures. HPV-related cytoplasmic clearing may be observed within the epithelium.

**i. Differential Diagnosis**

The differential diagnosis of squamous cell papilloma includes verruca vulgaris, verruciform xanthoma, condyloma acuminatum, papillary squamous cell carcinoma, and verrucous squamous cell carcinoma. The differential diagnosis of condyloma acuminatum includes squamous cell papilloma, verruciform xanthoma, papillary squamous cell carcinoma, and MFEH. The differential diagnosis of verruca vulgaris is verruciform xanthoma, squamous cell papilloma, and condyloma acuminatum, while MFEH is primarily differentially diagnosed with condyloma acuminatum (Betz, 2019; Andrade et al., 2019; Adel et al., 2020; Agho et al., 2020; Barrett & Boyopati, 2019).

**j. Prognosis and Management**

Simple excision is the primary treatment for squamous cell papilloma with a low recurrence rate and without malignant transformation or metastasis (ElNaggar, 2017; Andrade et al., 2019; Aldhafeeri et al., 2020). Condyloma acuminatum can be treated with excision, electrocautery, cryosurgery, or laser ablation, but has a tendency to recur and requires follow-up (ElNaggar, 2017; Chaturvedi & Chaturvedi, 2020; Palaia et al., 2021). Verruca vulgaris often regresses spontaneously, especially in children, while excision, cryotherapy, or laser provide a therapeutic success rate of 65–85%, although recurrence can still occur (ElNaggar, 2017; Betz, 2019; Mattoo & Bhatia, 2018). MFEH can also regress spontaneously. Therapy includes medication (topical salicylic acid as first choice, zinc supplementation in recalcitrant cases) or surgery, especially cryotherapy, with a generally good prognosis (Agho et al., 2020; Di Spirito et al., 2023).

**k. Comparison of the Characteristics of Benign Oral Cavity and Oropharyngeal Lesions Associated with HPV**

Benign lesions of the oral cavity and oropharynx associated with HPV include squamous cell papilloma, condyloma acuminatum, verruca vulgaris, and MFEH. Differences in the epidemiological characteristics of each lesion based on age and gender are shown in Table 1 (ElNaggar, 2017; Betz, 2019).

**Table 1. Comparison of the Epidemiology of Benign Oral Cavity and Oropharyngeal Lesions Associated with HPV (ElNaggar, 2017; Betz, 2019)**

Lesion	Age (years)	Gender
<i>Squamous Cell Papilloma</i>	Third to fifth decades	L = P
<i>Condyloma Acuminatum</i>	Young adults	L > P
<i>Verruca Vulgaris</i>	Third to fourth decade	L > P
<i>Multifocal Epithelial Hyperplasia</i>	First to second decade	P > L = 5 : 1

History, physical examination, lesion location, and macroscopic and microscopic features are crucial in establishing a diagnosis. A comparison of HPV types and the predilection location of each lesion can be seen in Table 2 (ElNaggar, 2017; Betz, 2019).

**Table 2. Comparison of HPV Types and Location of HPV-Related Benign Oral and Oropharyngeal Lesions (ElNaggar, 2017; Betz, 2019)**

Lesion	HPV types	Location
<i>Squamous Cell Papilloma</i>	6, 11	Palate, tongue, labial mucosa
<i>Condyloma Acuminatum</i>	6, 11, 16, 18	Labial mucosa, soft palate, frenulum
<i>Verruca Vulgaris</i>	2, 4	Labial mucosa, anterior tongue

<i>Multifocal Epithelial Hyperplasia</i>	1, 6, 11, 13, 16, 18, 32, 55	Labial mucosa, buccal mucosa, tongue
--	------------------------------	--------------------------------------

HPV is the primary cause of papillary lesions in the oral cavity and oropharynx. Transmission can occur vertically or horizontally through skin or mucosal contact, autoinoculation, breastfeeding, and amniotic fluid. The virus infects basal cells through epithelial microabrasions, replicates, and then spreads following keratinocyte differentiation. Most benign oral lesions are caused by low-risk HPV, particularly types 6 and 11, whose E6 and E7 proteins do not cause degradation of p53 and pRB, unlike high-risk HPV (Jonathan, 2018; ElNaggar, 2017; Betz, 2019).

The differential diagnosis of each lesion has different clinical and histopathological characteristics. A comparison of the differential diagnosis of each lesion can be seen in Table 3. The differential diagnosis of squamous cell papilloma includes verruca vulgaris, verruciform xanthoma, condyloma acuminatum, papillary squamous cell carcinoma, and verrucous squamous cell carcinoma. Meanwhile, the differential diagnosis of condyloma acuminatum includes squamous cell papilloma, verruciform xanthoma, papillary squamous cell carcinoma, and MFEH. The differential diagnosis of verruca vulgaris includes verruciform xanthoma, squamous cell papilloma, and condyloma acuminatum; while MFEH is mainly differentially diagnosed with condyloma acuminatum (ElNaggar, 2017; Betz, 2019; Chaturvedi & Chaturvedi, 2020; Mattoo & Bhatia, 2018; Barrett & Boyopati, 2019).

**Table 3. Differential Diagnosis of Benign Oral Cavity and Oropharyngeal Lesions Associated with HPV (ElNaggar, 2017; Betz, 2019)**

Lesion	Differential Diagnosis
<i>Squamous Cell Papilloma</i>	<i>Verruca Vulgaris Verruciform Xanthoma Condyloma Acuminatum Papillary Squamous Cell Carcinoma Verrucous Squamous Cell Carcinoma</i>
<i>Condyloma Acuminatum</i>	<i>Squamous Cell Papilloma Verruciform Xanthoma Papillary Squamous Cell Carcinoma Multifocal Epithelial Hyperplasia</i>
<i>Verruca Vulgaris</i>	<i>Verruciform Xanthoma Squamous Cell Papilloma Condyloma Acuminatum</i>
<i>Multifocal Epithelial Hyperplasia</i>	<i>Condyloma Acuminatum</i>

Simple excision is the primary treatment for benign HPV-related lesions. Condyloma acuminatum tends to recur and requires close follow-up, while verruca vulgaris and MFEH can regress spontaneously. In general, the prognosis for benign HPV-related lesions is good, and most oral HPV infections resolve spontaneously within 1–2 years, with an average of about 6 months (ElNaggar, 2017; Betz, 2019).

#### IV. DISCUSSION

Benign lesions of the oral cavity and oropharynx associated with HPV, namely squamous cell papilloma, condyloma acuminatum, verruca vulgaris, and MFEH, have overlapping clinical and histopathological characteristics, making a diagnosis difficult to establish based solely on clinical features. Although all lesions generally exhibit exophytic growth with papillary or verrucous morphology, differences in patient age, predilection site, HPV type, and histopathological features are important aspects in establishing the diagnosis and differentiating them from inflammatory lesions, precancerous lesions, and malignancies (Betz, 2019; Anaya-Saavedra et al., 2025).

Most benign oral lesions are associated with low-risk HPV, particularly genotypes 6 and 11. Unlike high-risk HPV types 16 and 18, which play a role in oropharyngeal carcinogenesis, the E6 and E7 proteins in low-risk HPV have a lower ability to inactivate the tumor suppressor proteins p53 and pRB, so that infection generally only causes benign epithelial proliferation. However, some lesions such as condyloma acuminatum and MFEH have also been reported to be associated with high-risk HPV genotypes, so interpretation of results must still consider the overall clinical and histopathological picture (Betz, 2019; Prabhu, 2023).

Anatomical location also plays a role in the diagnostic process. Most lesions are found on the labial mucosa, buccal mucosa, tongue, and palate, which are mucosal areas frequently exposed to microtrauma,

making it easier for HPV to infect basal cells through epithelial microabrasions. However, lesion location is not specific and cannot be used as the sole basis for diagnosis. Correlation between lesion location, patient age, clinical history, and histopathology remains necessary to improve diagnostic accuracy (Betz, 2019; Di Spirito et al., 2023).

Histopathology is the gold standard for differentiating benign HPV-related lesions from other lesions with similar clinical presentations. Koilocytes are a finding that supports HPV infection, while mitosoid bodies are characteristic of MFEH. Furthermore, histopathology is essential for differentiating benign lesions from verruciform xanthoma, papillary squamous cell carcinoma, and verrucous squamous cell carcinoma, as these lesions require different management and have different prognoses. In certain cases, molecular tests such as polymerase chain reaction (PCR) or in situ hybridization (ISH) can help identify the HPV genotype, especially in recurrent lesions or lesions with questionable histopathology (Betz, 2019; Anaya-Saavedra et al., 2025; Prabhu, 2023).

Simple excision remains the primary treatment option for most benign HPV-related lesions, with an excellent prognosis. However, condyloma acuminatum has a tendency to recur due to the potential persistence of HPV in the basal layer of the epithelium, requiring post-excision follow-up. In contrast, verruca vulgaris and MFEH can regress spontaneously, especially in children and adolescents. Education regarding the mechanisms of HPV transmission, the importance of maintaining oral hygiene, and regular monitoring of patients with risk factors such as immunodeficiency or HIV infection are necessary to reduce the risk of recurrence and improve treatment success (Palaia et al., 2021; Di Spirito et al., 2023; Anaya-Saavedra et al., 2025).

Overall, the diagnosis of benign oral and oropharyngeal lesions associated with HPV requires a multidisciplinary approach that integrates history taking, clinical examination, histopathology, and, if necessary, molecular testing. This approach not only improves diagnostic accuracy but also helps differentiate benign lesions from potentially malignant ones, enabling appropriate management and optimal patient prognosis (Betz, 2019; Anaya-Saavedra et al., 2025).

## V. CONCLUSION

Benign oral and oropharyngeal lesions associated with HPV infection include squamous cell papilloma, verruca vulgaris, condyloma acuminatum, and multifocal epithelial hyperplasia (MFEH). These lesions can occur in all age groups and are generally more common in men than in women, except for squamous cell papilloma, which has a similar incidence in both sexes, and MFEH, which is more common in women. The most common site of involvement is the labial mucosa, with HPV types 6 and 11 being the most frequently identified. The primary treatment for benign oral and oropharyngeal lesions associated with HPV is simple surgical excision.

## REFERENCES

- [1]. Adel B, Dammak N, Abdellatif C. Labial Verruca Vulgaris: A Case Report and Review of the Literature. *International Journal of Research Studies in Medical and Health Sciences*. 2020;5(5):45–47.
- [2]. Agho ET, Oluwadaisi AM, Oyetola EO, Ajike SO, Ayinde EA. Multifocal Epithelial Hyperplasia: A Case Report and Review of Literature. *Nigerian Journal of Dental Research*. 2020;5(2):185–190.
- [3]. Aldhafeeri K, Alshaikh M, Kilany F, et al. Unusual Manifestation of Benign Squamous Papilloma of the Uvula: A Case Report and Review of Literature. *Cureus*. 2020;12(1):6716.
- [4]. Anaya-Saavedra G, et al. Diagnostic Challenges and Clinical Management Gaps in HPV-Related Oral Papillary Lesions. *Frontiers in Oral Health*. 2025.
- [5]. Andrade SA, Pratavieira S, Paes JF. Oral Squamous Papilloma: A View Under Clinical, Fluorescence and Histopathological Aspects. *Einstein (São Paulo)*. 2019;17(2).
- [6]. Barrett AW, Boyopati RP. Verruciform Xanthoma of the Oral Mucosa: A Series of Eight Typical and Three Anomalous Cases. *International Journal of Surgical Pathology*. 2019:1–7.
- [7]. Betz SJ. HPV-Related Papillary Lesions of the Oral Mucosa: A Review. *Head and Neck Pathology*. 2019;13:80–90.
- [8]. Chaturvedi HT, Chaturevedi C. Oral Condyloma Acuminatum with Changes in Excretory Duct of Minor Salivary Gland: An Unusual Case Report and Review of Literature. *Journal of Oral and Maxillofacial Pathology*. 2020;24:588–589.

- [9]. Di Spirito F, et al. Oral Human Papillomavirus Benign Lesions and HPV Infection in Pediatric Patients: A Systematic Review. *Cancers*. 2023;15:1096.
- [10]. ElNaggar AK. WHO Classification of Head and Neck Tumours. 4th ed. Lyon: International Agency for Research on Cancer; 2017. p. 115–118.
- [11]. Eroschenko VP. in Fiore's Atlas of Histology with Functional Correlations. 12th ed. Philadelphia: Lippincott Williams & Wilkins; 2021. p.285–293.
- [12]. Focchi GRA, Bosse T, Kong CS. Condyloma Acuminatum. In: WHO Classification of Female Genital Tumours. 5th ed. Lyon: International Agency for Research on Cancer; 2020. p.422.
- [13]. Jonathan BM. Upper Aerodigestive Tract. In: Rosai and Ackerman's Surgical Pathology. 11th ed. Elsevier; 2018. p. 146–153.
- [14]. Magalhães GM, Vieira EC, Garcia LC, De Carvalho-Leite MLR, Guedes ACM, Araújo MG. Update on Human Papillomavirus – Part I: Epidemiology, Pathogenesis, and Clinical Spectrum. *Anais Brasileiros de Dermatologia*. 2021;96:1–16.
- [15]. Mariana GM, Larissa DM, Bruna AR. Elevated Prevalence of High-Risk HPV in Healthy Oral Mucosa of Users and Nonusers of Drugs in Northeastern Brazil. *Brazilian Oral Research*. 2019;33:1–5.
- [16]. Mattoo A, Bhatia M. Verruca Vulgaris of the Buccal Mucosa: A Case Report. *Journal of Cancer Research and Therapeutics*. 2018;14:454–456.
- [17]. Nishanth G, Aravindha BN, Anitha N, Malathi L. HPV-Related Oral Lesions: A Review. *Journal of Critical Reviews*. 2020;7:3562–3566.
- [18]. Palaia G, et al. Prevention of Recurrence of Oral HPV-Related Lesions. *Applied Sciences*. 2021;11:4194.
- [19]. Prabhu SR. Human Papillomavirus Associated Oral Lesions. Wiley; 2023.
- [20]. Sasha J. Betz. HPV-Related Papillary Lesions of the Oral Mucosa: *A Review*. Springer; 2019. p.1–10.
- [21]. Syrjänen S, Syrjänen K. HPV-Associated Benign Squamous Cell Papillomas in the Upper Aero-Digestive Tract and Their Malignant Potential. *Viruses*. 2021;13:3–10.