Clavicular Plasmacytoma With Lambda Light-Chain Monoclonal Gammopathy: A Case Report On The Limits Of Diagnostic Certainty When Disease Extent Assessment Is Incomplete

Anak Agung Fendy Triwicaksana[1]*, Kurrotun Ayni Bakrun[2]

[1]Department of Internal Medicine, Faculty of Medicine, Universitas Trunodjoyo Madura, Bangkalan, East Java, Indonesia
[2]Department of Anatomical Pathology, Faculty of Medicine, Universitas Trunodjoyo Madura, Bangkalan, East Java, Indonesia
Coresponden author:
Email: fendy.triwicaksana@trunojoyo.ac.id

Abstract.
Solitary plasmacytoma is a diagnosis of exclusion that holds only once systemic involvement has been ruled out through tissue clonality confirmation, complete bone marrow assessment, and whole-body imaging. This case report examines what may and may not be concluded when all three pillars are missing. A 57-year-old man was admitted with a destructive right clavicular mass of roughly 11.6 cm that had evolved over one year. Open biopsy concluded plasmacytoma without accompanying immunohistochemical staining. Serum protein electrophoresis showed no monoclonal peak, while serum immunofixation revealed a lambda light-chain monoclonal gammopathy. Two bone marrow aspiration attempts ended in dry tap, and trephine biopsy was never performed because the patient declined a repeat procedure. A seven-region radiographic survey found no additional lesions, while serum free light chain measurement and whole-body imaging were unavailable. The manuscript follows the CARE reporting framework, with a focused literature review drawing on Scopus-indexed sources. Item-by-item mapping against International Myeloma Working Group criteria shows that most myeloma-defining biomarkers are not assessable rather than negative. The label most consistent with the evidence is therefore clavicular plasmacytoma with lambda light-chain monoclonal gammopathy and incomplete disease extent assessment. The fall in pain score from 5 to 0 during admission is reported as a symptomatic outcome, not as evidence of tumour response. This case shows why investigations never performed must not be treated as negative results, above all in settings with constrained diagnostic resources.
Keywords: *plasmacytoma; clavicle; immunofixation; immunoglobulin light chains; multiple myeloma and diagnostic uncertainty.*

I. INTRODUCTION

Plasma cell neoplasms turn up rarely in day-to-day practice, and that rarity is what makes misclassification expensive. The global burden of multiple myeloma keeps climbing as populations age, with incidence and mortality projected to rise steeply through the middle of this century (Mafra et al., 2025). Cross-national registry analyses show the burden falling unevenly, shifting fastest in regions that have long been thin on data (Huang et al., 2022; Zhang et al., 2023). Recent reviews describe a disease whose treatment options change quickly while its diagnostic demands tighten (Malard et al., 2024; van de Donk et al., 2021). Solitary plasmacytoma sits at the other end of that spectrum. It accounts for a small share of cases, whether it arises from bone or soft tissue, and most clinicians meet it only a handful of times across a career (Charalampous et al., 2025; Hatipoğlu et al., 2025; Pham & Mahindra, 2019).

Rarity is also why the word "solitary" gets applied too early. The latest World Health Organization classification and current pathology reviews treat plasmacytoma as an entity that holds only once systemic involvement has been excluded, not as a descriptive label attached to a single mass (Fend et al., 2023). A European expert panel translated that into three working requirements: confirmation of a clonal plasma cell population in tissue, bone marrow examination covering aspiration and trephine biopsy alike, and imaging sensitive enough to hunt for a second lesion (Caers et al., 2018a). Until all three are in hand, what the clinician holds is a diagnosis of plasmacytoma with disease extent still unknown.

The gap between those two labels ends in different treatment. Solitary bone plasmacytoma is managed mainly with definitive radiotherapy and close surveillance, while multiple myeloma calls for systemic therapy from the outset (Dimopoulos et al., 2021; Tsang et al., 2018). International Myeloma Working Group criteria pair evidence of a plasma cell neoplasm with organ damage or specific biomarkers, together called *myeloma-*

defining events (Rajkumar, 2024; Rajkumar et al., 2014). The design forces treatment decisions onto data actually obtained rather than onto clinical impression. The most recent European guideline update presses the same point: determining disease extent belongs to the diagnosis itself, not to an optional later step (Dimopoulos et al., 2025).

Three investigative gaps recur in the field, and all three appear together in the case reported here. The first concerns monoclonal protein. Serum protein electrophoresis has detection limits measured across multiple centres, and it does not always show a monoclonal peak in light-chain disease (Jacobs et al., 2020; Turner et al., 2020). Immunofixation and serum free light chain measurement catch the patients electrophoresis misses, and in light-chain myeloma the free light chain ratio becomes the key parameter (Heaney et al., 2017; Singh, 2020). The second gap sits in the bone marrow. A failed aspiration, or dry tap, is no rare event; it has long been known to accompany meaningful marrow pathology more often than not (Humphries, 1990; Ozkalemkas et al., 2005). The third gap sits in imaging. Conventional radiographic survey is less sensitive than whole-body low-dose computed tomography, whole-body magnetic resonance imaging, or positron emission tomography, so a negative result excludes little (Hillengass et al., 2017; Hillengass et al., 2019).

The solitary plasmacytoma literature has moved on one important point. Minimal bone marrow involvement no longer counts as a footnote. A recent multicentre study shows that patients with bone plasmacytoma and minimal marrow involvement carry a progression risk profile distinct from those with none at all (Lim et al., 2026). Analyses of cytogenetic abnormalities and large institutional cohorts point the same way (Katodritou et al., 2025; Yadav et al., 2023). Where marrow status is unknown, the risk stratification that drives treatment is unknown with it.

What we set out to fill is the handling of that uncertainty in the open. Case reports on plasmacytoma tend to close with a definitive diagnosis, while systematic discussion of what may and may not be concluded from incomplete investigation stays scarce. Yet work on communicating diagnostic uncertainty shows that acknowledging the limits of the data improves decisions without costing patient trust (Dahm et al., 2023; Meyer et al., 2021). The need bites harder in services where advanced imaging and specialised assays are rationed, as the imaging recommendations drafted for the Asian region make plain (Nagarajan et al., 2025).

This report presents a middle-aged man with a destructive right clavicular mass reported on biopsy as plasmacytoma, with no monoclonal peak on electrophoresis, a lambda light-chain gammopathy on immunofixation, and two bone marrow aspiration attempts that both ended in dry tap. Our aims run in sequence. We document the clinical course and investigative results as they stand, including the investigations never done; we set out diagnostic reasoning that keeps negative findings apart from tests never performed; and we draw practical implications for clinicians facing a comparable combination, above all in resource-constrained settings. The question we answer: how far can the label "solitary plasmacytoma" be sustained when free light chain assessment, trephine biopsy, and whole-body imaging are unavailable, and what follows from holding that uncertainty honestly in the medical record and in the literature.

II. METHODS

Design and source of case data

This is a single-patient case report built retrospectively from the medical documentation of an adult treated at a tertiary referral hospital in December 2018. We drew all clinical data from nursing records, laboratory results, radiology reports, and anatomical pathology reports held in the medical file. Nothing was reconstructed from memory, interpolated, or estimated from other values. Where an investigation appears in the notes but its result is absent from the file, we report that state as data unavailable rather than as a normal or negative result. We hold that distinction throughout the manuscript because it carries the argument.

The report follows the CARE reporting framework, which sets mandatory items covering patient information, clinical findings, timeline, diagnostic assessment, therapeutic interventions, outcomes and follow-up, and patient perspective (Gagnier et al., 2014). We used the CARE explanation and elaboration document as an operational reference when deciding how deep to report each item, above all the diagnostic assessment item, which requires methodological limitations to be stated (Riley et al., 2017). The clinical timeline was rebuilt from recorded dates and is laid out in tabular form so readers can inspect the sequence themselves.

Unit conversion and presentation of laboratory values

Laboratory values appear in the original units as recorded in the file, followed by conversion to International System units in parentheses where relevant. Conversion is arithmetic and changes no meaning. The testing laboratory's reference intervals were absent from the file, so interpretation against normal limits rests on thresholds used in international diagnostic criteria rather than on assumed local ranges. Results from different sampling occasions were never merged into a single value. Differences in lesion size between imaging modalities were likewise not treated as evidence of change in tumour size, since the measurement planes and protocols do not match.

Literature search and selection

The discussion is a focused literature review rather than a systematic one. Searches ran in the Scopus database, combining keywords across title, abstract, and keyword fields: solitary plasmacytoma, solitary bone plasmacytoma, multiple myeloma diagnostic criteria, serum protein electrophoresis, immunofixation, serum free light chain, non-secretory myeloma, bone marrow trephine biopsy, dry tap, whole-body imaging, skeletal survey, and radiotherapy plasmacytoma. The primary publication window covers the past five years. We made exceptions for foundational references that remain the standard point of reference, including the International Myeloma Working Group diagnostic criteria, the CARE reporting guideline, and the classic literature on the clinical meaning of dry tap.

Every candidate reference passed two verification layers before use. The first confirmed that the article is indexed in Scopus with its authentic metadata. The second confirmed that the digital object identifier resolves in the Crossref catalogue, so each bibliography entry points to the right article. References failing either layer were dropped. Priority went to consensus guidelines, multicentre studies, and registry-based cohorts; case reports appear sparingly, only to illustrate comparable clinical patterns, never as evidence of frequency or effectiveness.

Analytical framework

Case analysis ran in three deliberately separated steps so that every conclusion can be traced back. The first sorted all findings into three categories: documented positive findings, negative findings genuinely tested, and investigations not performed or with results unavailable. The second mapped each item of the multiple myeloma diagnostic criteria against those categories, exposing which items could be assessed and which had unknown status. The third tested three alternative diagnostic labels, namely solitary plasmacytoma, plasmacytoma with minimal marrow involvement, and multiple myeloma, against the strength of the available evidence, then selected the most conservative label consistent with the data. The approach follows recommendations that diagnostic uncertainty be stated explicitly and in structured form rather than hidden behind language that sounds definitive (Cox et al., 2021; Rising et al., 2020).

Ethical considerations

This case report was built from anonymised medical record data. All direct identifiers were removed and dates appear at the level of month and year to cut the risk of re-identification. Written consent for publication and the status of institutional ethics committee review are administrative items the corresponding author must complete before submission; neither can be asserted from the clinical file alone.

Results: Case Illustration

History and course of illness

A 57-year-old man was admitted to a referral hospital in December 2018 with pain and a lump in the right clavicular region. The pain began around December 2017, at first only on palpation or during activity, later worsening until it was present at rest. Around February 2018 a lump appeared and kept enlarging, along with restricted right arm movement and weight loss the notes never quantified. The complaints interfered with his daily work. He reported no lumps elsewhere, no recurrent fever, no spontaneous bleeding. He denied any history of blood disorders, hypertension, or diabetes mellitus.

He first sought medical attention in June 2018, roughly six months after symptoms began, and underwent evaluation of the clavicular mass. Open biopsy was done before referral; the result, available in August 2018, concluded plasmacytoma. After referral he underwent computed tomography and haematological evaluation. In November 2018 two bone marrow aspiration attempts were made and both

yielded a dry tap. He then declined repeat aspiration, and the file holds no bone marrow trephine biopsy result. Table 1 summarises the sequence of clinical events from symptom onset to the end of admission.

Table 1. Clinical timeline from symptom onset to the end of admission

Time	Clinical event	Documentation source
December 2017	Onset of right clavicular pain, initially only on palpation or during activity	History
February 2018	A progressively enlarging lump appeared; right arm movement restricted; unquantified weight loss	History
June 2018	First medical contact. Chest radiography: right upper hemithorax mass, right clavicular destruction, trachea displaced to the left	Radiology report
August 2018	Open biopsy result of the clavicular mass available; pathology conclusion: plasmacytoma	Anatomical pathology report
September 2018	Contrast-enhanced head and neck CT: right clavicular destruction; enhancing soft tissue mass with necrotic areas, ± 7.27 × 9.97 × 8.39 cm	Radiology report
October 2018	Thoracic CT: mass ± 8.8 × 8.2 × 7.6 cm; no pulmonary metastases; sub-centimetre lymph nodes without pathological confirmation	Radiology report
November 2018	Two bone marrow aspiration attempts, both dry tap. Patient declined repeat aspiration; trephine biopsy not performed	Nursing records
December 2018 (early)	Admission; right clavicular mass ± 11.6 cm, hyperaemic, hard, fixed; VAS 5. Paracetamol 4 × 500 mg, later codeine 3 × 10 mg	Nursing records
December 2018	Seven-region radiographic survey (skull, thoracolumbar vertebrae, pelvis, right humerus and forearm, left femur and leg): no additional lesions	Radiology report
December 2018	Chemotherapy labelled VAD (epirubicin, vincristine, dexamethasone); radiotherapy planned, no evidence of delivery recorded	Nursing records
6, 8, and 18 December 2018	VAS pain scores of 4, 1, and 0 respectively	Nursing records
18 December 2018	Serum immunofixation: lambda light-chain monoclonal gammopathy; patient directed to outpatient follow-up	Laboratory result and nursing records

Time	Clinical event	Documentation source
After discharge	Follow-up, remeasurement of the mass, and serial monoclonal protein testing not documented	Not available

Sumber: Source: compiled by the authors from the patient's medical record; timeline structure follows the mandatory items of the CARE framework (Gagnier et al., 2014)

Physical examination findings

Local examination found a mass in the right clavicular region roughly 11.6 cm across. The overlying skin looked hyperaemic. The mass was hard, tender on palpation, and fixed both to the skin and to the underlying structures. Flexion and abduction of the right shoulder were limited. The initial pain score on a visual analogue scale was 5. Body weight was recorded as 42 kg and height as 155 cm, giving a body mass index of about 17.5 kg/m² when calculated from those two measurements. Documented physical examination found no peripheral lymphadenopathy and no hepatosplenomegaly.

Laboratory findings

Table 2 sets out the principal laboratory results together with the plasma cell evaluation. Haemoglobin ranged from 10.6 to 10.8 g/dL across two measurements. Initial leukocyte and platelet counts were 4.54 × 10^9/L and 202 × 10^9/L respectively, both within normal limits. Serum creatinine was 0.98 mg/dL on initial testing and 0.85 mg/dL on repeat testing, while total calcium was 8.6 mg/dL. Total protein and albumin were 6.5 and 4.5 g/dL, with a gamma globulin fraction of 0.3 g/dL according to the available summary.

Table 2. Laboratory results and plasma cell evaluation with their evidence status

Investigation	Recorded result	Interpretive note
Haemoglobin	10.6–10.8 g/dL (106–108 g/L)	Above the IMWG absolute anaemia threshold (< 10 g/dL); the testing laboratory's reference limits were unavailable
Initial leukocytes and platelets	4.54 × 10^9/L and 202 × 10^9/L	Both within normal limits; no cytopenia
Peripheral blood smear	Normochromic normocytic anaemia with anisopoikilocytosis; 2% normoblasts; myelocytes and metamyelocytes; atypical lymphocytes	Leukoerythroblastic pattern; the cause of anaemia was never investigated
Serum creatinine	0.98 then 0.85 mg/dL (87 then 75 µmol/L)	Does not meet the IMWG renal insufficiency criterion
Total calcium	8.6 mg/dL (2.15 mmol/L)	No hypercalcaemia
Total protein and albumin	6.5 g/dL and 4.5 g/dL (65 g/L and 45 g/L)	—
Gamma globulin fraction	0.3 g/dL (3 g/L)	Reported as reduced; not a substitute for free light chain quantification
Serum protein electrophoresis	No monoclonal peak	Detection limits are constrained in light-chain disease (Turner et al., 2020)
Serum immunofixation	Lambda light-chain monoclonal gammopathy	Qualitative; conveys no information about the site of production
Serum free kappa, lambda, and involved/uninvolved ratio	Not available	Myeloma-defining biomarker cannot be assessed
Urinary Bence Jones protein	Negative	Assay method and type of urine collection not recorded
Bone marrow aspiration	Dry tap on two attempts	Yields no estimate of plasma cell percentage

Investigation	Recorded result	Interpretive note
Bone marrow trephine biopsy	Not performed	Bone marrow status unknown
Open biopsy histopathology	Diffuse proliferation of round-nucleated cells, some with eccentric nuclei, thin to clear cytoplasm, 2–3 mitoses per high-power field; conclusion of plasmacytoma	Accepted as written
Tissue immunohistochemistry (plasma cell markers, kappa and lambda)	Not available	Tumour clonality not independently verified

Sumber: Source: compiled by the authors from the patient's medical record; interpretive thresholds follow (Rajkumar et al., 2014)

The peripheral blood smear was reported as normochromic normocytic anaemia with anisopoikilocytosis, alongside 2% normoblasts, immature granulocytes in the form of myelocytes and metamyelocytes, and atypical lymphocytes. Leukocyte and platelet counts were judged normal on the same smear. No further investigation established the cause of the anaemia, whether iron studies, vitamin B12 and folate levels, reticulocyte count, or haemolysis markers. The meaning of the leukoerythroblastic picture could not be pursued either, since the bone marrow was never successfully assessed.

Serum protein electrophoresis showed no monoclonal peak, and the examination note in fact described a reduced gamma fraction. Urinary Bence Jones protein was reported as negative, though neither the assay method nor the type of urine collection appears in the file. Serum immunofixation came back only towards the end of the admission and was reported as lambda light-chain monoclonal gammopathy. Serum free kappa and lambda light chain levels and the involved/uninvolved ratio were unavailable. The treating team worked with a diagnosis of clavicular bone plasmacytoma presumed solitary. On the data genuinely present in the file, we retain uncertainty about the extent of systemic disease.

Imaging and histopathology findings

Chest radiography in June 2018 was reported as showing a mass in the right upper hemithorax destroying the right clavicle and displacing the trachea to the left. Contrast-enhanced computed tomography of the head and neck in September 2018 showed destruction of the right clavicle with an enhancing soft tissue mass containing necrotic areas, measuring roughly 7.27 × 9.97 × 8.39 cm. Computed tomography of the thorax in October 2018 described a mass of roughly 8.8 × 8.2 × 7.6 cm with no pulmonary metastases. Sub-centimetre lymph nodes were reported at several sites without pathological confirmation. We did not treat the difference in recorded dimensions between the two examinations as evidence of change in tumour size, since the measurement planes, protocols, and indications are not comparable.

The microscopic description of the open biopsy reported diffuse proliferation of round-nucleated cells, some with eccentric nuclei, thin to clear cytoplasm, and roughly two to three mitoses per high-power field, dispersed among fibrous tissue and cartilage. The pathology report concluded plasmacytoma. The file holds no immunohistochemical results, neither plasma cell lineage markers nor kappa and lambda light chain staining on tissue, so tumour clonality could not be verified independently of that report.

A skeletal radiographic survey was performed in December 2018 covering the skull, thoracolumbar vertebrae, pelvis, right humerus and forearm, and left femur and leg. No additional osteolytic or osteoblastic lesions were found in the bones examined. This was a conventional radiographic survey even though the initial documentation used the term bone scan x-rays, so the file's wording needs reading with care. No integrated positron emission tomography with computed tomography, whole-body magnetic resonance imaging, or whole-body low-dose computed tomography results were available. Figure 1 summarises the evidence status for each evaluation component.

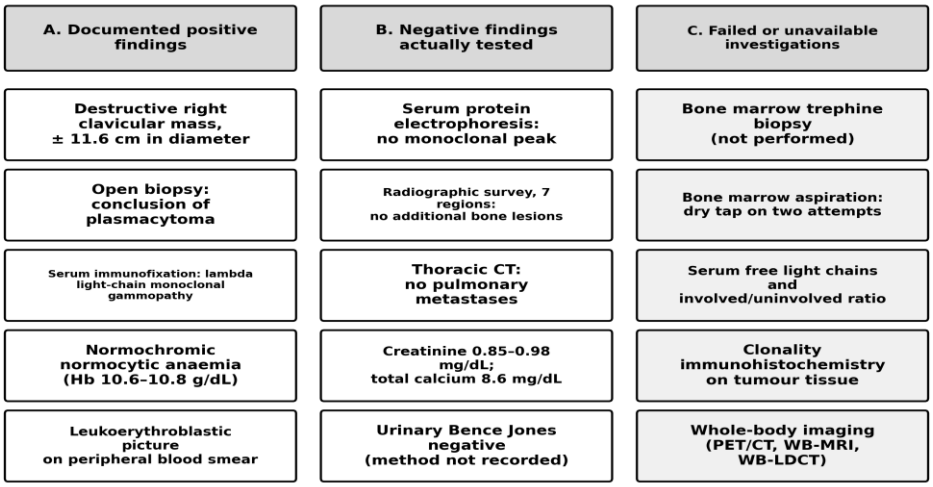

Fig. 1. Sorting of case findings by evidence status: documented positive findings, negative findings actually tested, and investigations that failed or were unavailable. Source: compiled by the authors from the patient's medical record

Management and in-hospital outcome

Symptomatic management began with oral paracetamol 500 mg four times daily, later joined by oral codeine 10 mg three times daily. The documentation records chemotherapy labelled VAD, with the listed components being epirubicin, vincristine, and dexamethasone. Radiotherapy consultation or enrolment was also planned, though the file holds no evidence of delivery, treatment field, or dose. Neither the clinical rationale for the regimen nor the team's thinking on treatment sequencing was documented. We can record what was given without judging whether the decision was sound.

The recorded pain score fell steadily, from 5 at the start of admission to 4 on 6 December, 1 on 8 December, and 0 on 18 December 2018. At the final assessment the patient was advised to continue outpatient follow-up. No repeat measurement of mass size after treatment, no serial monoclonal protein testing, no structured toxicity data against standard criteria, and no follow-up records after discharge were available. What can honestly be reported as improvement therefore stops at pain during the admission, and does not reach tumour response. The patient's perspective on his illness and its treatment was not documented in the file; we acknowledge that omission as a departure from the reporting completeness the CARE framework recommends (Gagnier et al., 2014).

III. DISCUSSION

The central problem here is classification, not recognition

A destructive clavicular mass with a biopsy conclusion of plasmacytoma suffices to recognise a plasma cell proliferation in bone. The next question goes unanswered: how far the disease extends. Contemporary classification treats solitary plasmacytoma as a diagnosis of exclusion valid only after systemic involvement has been ruled out through adequate bone marrow examination and imaging (Fend et al., 2023; Rajkumar, 2024). The European expert panel puts the same requirement in operational terms, placing aspiration together with trephine biopsy and sensitive imaging ahead of the solitary label (Caers et al., 2018a). Neither requirement was met here. The failure to meet them traces to investigations that were unsuccessful or never performed, not to negative results.

The soft tissue component accompanying the bone lesion raised the question of whether to call this extramedullary plasmacytoma. An expert review of soft-tissue plasmacytomas makes clear that a soft tissue mass contiguous with and arising from a bone lesion stays classified as paraskeletal disease rather than true extramedullary disease (Rosiñol et al., 2021). The distinction matters because the two groups differ in biological behaviour and prognosis, as a systematic review of extramedullary disease in myeloma shows

(Bansal et al., 2021; Bladé et al., 2022). With clear clavicular destruction at the centre of the lesion, paraskeletal classification fits the evidence best.

Verification of tumour clonality is a second gap worth stating openly. The morphological description in the file is consistent with plasma cells, but immunohistochemical staining and assessment of light chain restriction in tissue were never documented. Establishing clonality, whether by immunohistochemistry, flow cytometry, or sequencing-based assays, has long been standard in characterising plasma cell neoplasms (Arcila et al., 2019; Fend et al., 2023). A case report showing co-expression of both light chains in bone plasmacytoma demonstrates how morphology alone can mislead without immunophenotypic confirmation (Matsuoka et al., 2021). We accept the pathology conclusion as written and claim no independent verification of its clonality.

The clavicle is an uncommon site, and that alone warrants caution

The anatomical distribution of solitary bone plasmacytoma is dominated by the axial skeleton, the vertebrae above all, while the shoulder girdle turns up far less often (Pham & Mahindra, 2019). Available case series and systematic reviews show that lesions outside typical sites tend to present in ways that mimic other conditions, from chronic tibial pain to a jaw mass, stretching the interval between symptom onset and diagnosis (Suryavanshi et al., 2021; Yang et al., 2023). Vertebral and high cervical lesions are often diagnosed only once they produce compressive symptoms (Li et al., 2020; Tan et al., 2021). Our case follows the same pattern: symptoms ran for about six months before the first medical contact, and the mass already measured more than ten centimetres when it was evaluated.

Large size at diagnosis is more than a descriptive note. A mass that has grown over a long period gives the plasma cell clone time to expand and raises the odds that disease has spread past one site. A late presentation of this kind lifts the evidentiary threshold required before the solitary label is applied. In this case, that requirement met the point where investigative availability was thinnest.

Discordance between electrophoresis and immunofixation is the most informative finding

Electrophoresis without a monoclonal peak alongside immunofixation showing a lambda gammopathy is no contradiction. The two tests measure different things and carry different detection limits. A multicentre accuracy study across dozens of laboratories showed that serum protein electrophoresis has quantitation limits varying between laboratories and often fails to display low-concentration monoclonal protein (Turner et al., 2020). The second part of that study showed detection limits for small monoclonal proteins to be more challenging still, above all when monitoring patients with faint peaks (Jacobs et al., 2020). This pattern explains why a clean electrophoresis result must never be read as evidence that no plasma cell disorder exists.

Light-chain disease is the scenario that most often produces the pattern seen in this patient. In light-chain myeloma no intact immunoglobulin is produced, so the classic monoclonal peak in the gamma region frequently fails to appear, while monoclonal light chains stay detectable by immunofixation or free light chain measurement (Bolarinwa et al., 2025; Heaney et al., 2017). Clinical characterisation of this group shows a higher risk of renal damage and outcomes differing from intact immunoglobulin myeloma (Jin et al., 2021). Immunochemical studies in myeloma cohorts also show that serum and urine testing used together improves paraprotein detection over serum testing alone (Lyubimova et al., 2018). Those findings support complementary assay panels, though they supply no sensitivity estimate specific to this patient.

The positive immunofixation here adds one important piece of information and opens a new question at the same time. What it adds is confirmation that a circulating clonal plasma cell product exists, which strengthens the pathology conclusion. What stays open: whether that production arises solely from the clavicular mass or also from a plasma cell population in the bone marrow. Immunofixation cannot settle it, being qualitative and silent on the source. The positive result raises suspicion of systemic disease without proving it.

The gamma globulin fraction is no substitute for free light chain measurement

The temptation to use the gamma globulin figure of 0.3 g/dL as a proxy for monoclonal protein burden has to be refused outright. A monoclonal peak is a pattern on electrophoresis, while free light chain concentration comes from a separate immunochemical measurement with its own units and reference intervals. Comparisons between commercially available free light chain assays show meaningful differences in results even on identical samples, so a value from one method cannot simply be swapped for another (Fleming et al.,

2020; Schieferdecker et al., 2020). That inter-assay variability is documented in clinical laboratory reviews as well, and it is why monitoring is advised to stay with one method (Caponi et al., 2020).

The involved/uninvolved free light chain ratio holds a special place in the diagnostic criteria, since a ratio of 100 or more is itself a myeloma-defining biomarker (Rajkumar, 2022; Rajkumar et al., 2014). In light-chain monoclonal gammopathy this ratio also drives risk stratification, as a flow cytometry substudy within a large screening population shows (Óskarsson et al., 2024). Its interpretation demands extra care in patients with reduced renal function, because the reference range for the ratio shifts in chronic kidney disease (Long et al., 2022). This patient's serum creatinine sat in a range showing no severe impairment, so nothing technical stood in the way of interpreting the ratio had the test been done.

The negative urinary Bence Jones result needs placing in proportion too. Neither the assay method nor the type of urine collection was recorded, and both govern sensitivity. Evidence from a large clinical trial shows serum free light chain measurement outperforming urine testing for response assessment in light-chain myeloma, so a negative urine result does not equal a negative serum result (Dejoie et al., 2016). Contemporary laboratory guidance places serum electrophoresis, immunofixation, and free light chain assays as a complementary panel rather than interchangeable alternatives (Caers et al., 2018b; Singh, 2020). More recent mass spectrometry-based detection has shown sensitivity higher still than conventional immunofixation in large series (Dasari et al., 2022; Murray et al., 2021).

Two dry taps leave a question, not an answer

Failure to obtain an aspirate yields no estimate of plasma cell percentage and cannot be used to call the bone marrow normal. The classic literature on dry tap shows the reverse: aspiration failure frequently accompanies meaningful marrow pathology, including neoplastic infiltration and fibrosis, so the event ought to trigger further investigation instead of closing the evaluation (Humphries, 1990). A review of unsuspected non-haematological malignancy likewise shows trephine biopsy providing information aspiration alone does not (Ozkalemkas et al., 2005). A recent methodological review of plasma cell estimation in bone marrow reinforces that aspiration and trephine biopsy do not always agree, and that biopsy is required when the infiltrate is focally distributed (Gantana et al., 2024).

Advances in marrow assessment make this loss of information costlier still. Next-generation flow cytometry now detects clonal plasma cells well below the limit of morphological detection, and that capability has become a reference standard in residual disease assessment in myeloma (Paiva et al., 2020). The distance between what could be known and what is actually known in this case widens with the technology rather than narrowing.

The patient's refusal of repeat aspiration belongs in the record as a real and legitimate barrier to evaluation, never as grounds for concluding anything about marrow status. Two options remain in such a situation: offer trephine biopsy, which differs technically from repeated aspiration, or substitute imaging able to assess marrow involvement indirectly. Whole-body magnetic resonance imaging with diffusion weighting is the modality recommended for exactly that purpose when solitary plasmacytoma is suspected (Chakraborty et al., 2023; Hillengass et al., 2019).

The leukoerythroblastic picture on the peripheral smear adds further reason not to close the marrow evaluation. Normoblasts and immature granulocytes in peripheral blood prove no infiltration, since the pattern arises across a range of conditions, but clinicians routinely read it as a signal to consider processes disturbing marrow architecture. Here that signal coincided with unexplained anaemia and with two failed aspirations. The combination leaves any statement that the bone marrow is uninvolved unsupported by data.

Myeloma criteria need assessing item by item, not condensing into CRAB negative

A summary phrase such as "CRAB negative" hides an important difference between items genuinely assessed and items that could not be. The International Myeloma Working Group anaemia criterion covers haemoglobin below 10 g/dL or more than 2 g/dL below the lower limit of normal, with a causal link to the plasma cell disorder (Rajkumar et al., 2014). This patient's haemoglobin of 10.6 to 10.8 g/dL misses the first absolute threshold. The testing laboratory's reference limits were unavailable and the cause of the anaemia was never investigated, so the second item cannot be assessed. Recorded creatinine and calcium showed no severe derangement. A destructive bone lesion is clearly present, yet in plasmacytoma a single lesion belongs to the

definition, so its presence does not automatically satisfy the criterion for myeloma-related bone damage (Rasch et al., 2020; Terpos et al., 2021).

The myeloma-defining biomarkers run into the same wall. None of the three, namely clonal bone marrow plasma cells of 60% or more, an involved/uninvolved free light chain ratio of 100 or more, and more than one focal lesion on magnetic resonance imaging, could be evaluated in this patient (Cowan et al., 2022; Rajkumar, 2024). That situation differs fundamentally from one in which all three were tested and came back negative. Table 3 presents the item-by-item mapping against the case data, and that mapping is what underpins the statement that multiple myeloma has not been excluded.

Table 3. Item-by-item mapping of multiple myeloma diagnostic criteria against the case data

Criterion item	Threshold or definition	Case data	Assessment status
Evidence of a clonal plasma cell neoplasm	Biopsy-proven plasmacytoma, or clonal bone marrow plasma cells ≥ 10%	Open biopsy concluded plasmacytoma; clonality immunohistochemistry unavailable	Met per the pathology report; not yet immunophenotypically verified
C — Hypercalcaemia	Serum calcium > 1 mg/dL above the upper limit of normal or > 11 mg/dL	Total calcium 8.6 mg/dL	Assessable; not met
R — Renal insufficiency	Creatinine clearance < 40 mL/min or serum creatinine > 2 mg/dL	Creatinine 0.85–0.98 mg/dL	Assessable; not met
A — Anaemia	Haemoglobin > 2 g/dL below the lower limit of normal, or < 10 g/dL, attributable to the plasma cell disorder	Haemoglobin 10.6–10.8 g/dL; local reference limits and aetiology unavailable	Partial; absolute threshold not met, relative threshold and attribution not assessable
B — Bone lesions	One or more osteolytic lesions on radiographic survey, CT, or PET/CT	One destructive clavicular lesion; seven-region radiographic survey without additional lesions; whole-body imaging not performed	Not fully assessable; imaging coverage limited
Biomarker 1	Clonal bone marrow plasma cells ≥ 60%	Dry tap twice; trephine biopsy not performed	Not assessable
Biomarker 2	Involved/uninvolved free light chain ratio ≥ 100	Serum free light chain measurement unavailable	Not assessable
Biomarker 3	More than one focal lesion (≥ 5 mm) on magnetic resonance imaging	MRI not performed	Not assessable

Sumber: Source: compiled by the authors from (Cowan et al., 2022; Rajkumar, 2024; Rajkumar et al., 2014)

The alternative labels sometimes weighed in comparable situations fail to fit as well. Monoclonal gammopathy of undetermined significance requires the absence of target organ damage and of related bone lesions, while this patient has a destructive tumour reported as plasmacytoma (Rajkumar & Kumar, 2025). Smouldering myeloma requires assessment of bone marrow plasma cell burden, which is precisely what is missing. Non-secretory and oligosecretory myeloma cannot be applied either, since this patient's

immunofixation is positive while both categories are defined by the absence of detectable monoclonal protein (Corso & Mangiacavalli, 2017; Migkou et al., 2020; Nandakumar et al., 2020; Sun et al., 2023).

A negative radiographic survey excludes little

The absence of additional lesions on radiographic survey is useful information, but its coverage and sensitivity need stating. The International Myeloma Working Group study comparing whole-body computed tomography with conventional radiographic survey showed the conventional modality missing a proportion of lesions detected by computed tomography (Hillengass et al., 2017). Other cross-modality comparisons reinforce the pattern, for low-dose computed tomography as well as for whole-body magnetic resonance imaging and positron emission tomography (Messiou et al., 2021; Simeone et al., 2019). Interobserver agreement is reported to be better with whole-body magnetic resonance imaging than with whole-body computed tomography for assessing disease burden (Lai et al., 2020). Table 4 summarises the modality comparison and its implications for this case.

Table 4. Comparison of imaging modalities in plasma cell disorder evaluation and their application to this case

Modality	Role in plasma cell disorder evaluation	Status in this case
Conventional radiographic survey	The oldest modality; requires substantial bone mass loss before lesions become visible, making it the least sensitive (Hillengass et al., 2017)	Performed across seven regions; no additional lesions
Whole-body low-dose computed tomography	Replaces radiographic survey as the minimum standard; detects more lytic lesions at an acceptable dose (Mena et al., 2022; Simeone et al., 2019)	Not performed
Whole-body magnetic resonance imaging, including diffusion weighting	Assesses marrow infiltration before bone destruction occurs; recommended for excluding a second focal lesion in suspected solitary plasmacytoma (Hillengass et al., 2019; Lai et al., 2020; Messiou et al., 2021)	Not performed
Integrated positron emission tomography with computed tomography	Assesses lesion metabolic activity, extramedullary disease, and treatment response (Chakraborty et al., 2023; Zamagni et al., 2019)	Not performed
Regional contrast-enhanced computed tomography	Assesses local extension of the mass and its relation to surrounding structures; does not substitute for whole-body examination (Baffour et al., 2020; Ormond Filho et al., 2019)	Performed for the head and neck and thoracic regions

Sumber: Source: compiled by the authors from (Hillengass et al., 2017; Hillengass et al., 2019; Nagarajan et al., 2025; Zamagni et al., 2019)

Consensus imaging recommendations place whole-body examination as the minimum standard in evaluating monoclonal plasma cell disorders, and cite specifically the need to exclude a second lesion before assigning the solitary designation (Hillengass et al., 2019; Zamagni et al., 2019). Contemporary imaging reviews carry the same message with emphasis on choosing the modality according to the clinical question (Baffour et al., 2020; Ormond Filho et al., 2019; Rodríguez-Laval et al., 2024; Wu et al., 2021). Realistic minimum requirements have been addressed specifically, including for settings short of equipment (Mena et

al., 2022). Recommendations drafted by the Asian myeloma network sit closer to the service context of this region, including the order of priority when not all modalities are on hand (Nagarajan et al., 2025).

The neck and thoracic computed tomography performed in this patient assessed specific anatomical regions according to their original indications, so the results cannot stand in for a whole-body examination. Weighing all these limitations, the label most consistent with the available evidence is clavicular plasmacytoma with lambda light-chain gammopathy and incomplete assessment of disease extent. Figure 2 sets out the reasoning pathway linking findings, evidence status, and the chosen label.

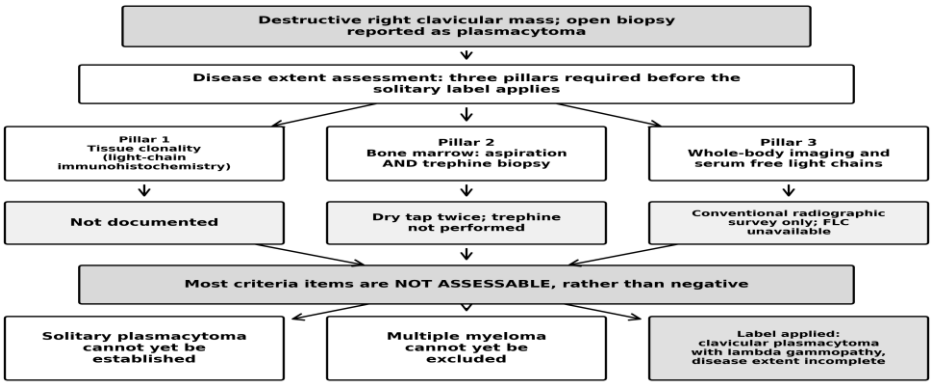

Fig. 2. Diagnostic reasoning pathway from initial findings to the label retained. Source: compiled by the authors from (Caers et al., 2018a; Rajkumar, 2024)

Minimal marrow involvement changes what treatment decisions mean

Literature from recent years has sharpened rather than relaxed the question of bone marrow status. A multicentre study of bone plasmacytoma with and without marrow involvement shows differing progression risk between the two groups, so marrow status works as a stratification determinant rather than a supplementary note (Lim et al., 2026). Analysis of cytogenetic abnormalities in solitary bone plasmacytoma points the same way from the standpoint of disease biology (Yadav et al., 2023). Institutional cohorts and national registries report a substantial proportion progressing to myeloma within the first few years (Ganzel et al., 2022; Katodritou et al., 2025; Nakaya et al., 2020; Shen et al., 2021). Case reports of rapid conversion from plasmacytoma with minimal marrow involvement to symptomatic myeloma illustrate the clinical cost when that status is overlooked (Kawahara et al., 2023; Khurana et al., 2025).

Definitive radiotherapy is the primary treatment for solitary plasmacytoma, with good local control across large and institutional series (Alghisi et al., 2021; Curry et al., 2020; Elsayad et al., 2020; Tsang et al., 2018). Newer technical approaches, stereotactic body radiotherapy among them, are under test in this context (Mauro et al., 2021). The role of additional systemic therapy in solitary plasmacytoma, by contrast, is not yet standard and stays a research question, whether as conventional chemotherapy or as immunomodulatory agents combined with radiotherapy (Ascione et al., 2023; Mheidly et al., 2019; Mignot et al., 2020). Serum myeloma protein concentration in plasmacytoma has been reported to carry predictive value for progression, which again highlights the quantitative measurement this case lacks (Chang et al., 2020).

The recorded chemotherapy regimen in this patient can be reported only as a documented action. Without records of the team's reasoning, radiotherapy availability at the time, or any pressing clinical circumstances, no fair appraisal of that decision is possible. What can be concluded: treatment decisions in such situations should ideally wait for clarity on bone marrow status and disease extent, since those two determinations are what separate an indication for definitive radiotherapy from an indication for systemic therapy (Dimopoulos et al., 2021; Dimopoulos et al., 2025; Kumar et al., 2020).

Pain improvement is not evidence of tumour response

The fall in pain score from 5 to 0 spanned a period that included both analgesia and chemotherapy. A temporal sequence of that kind permits no attribution of cause to any single intervention. Freedom from pain at the end of the admission is likewise no evidence of remission, since the mass was not remeasured, imaging was not repeated, and laboratory response parameters were unavailable. Response assessment in plasma cell

disorders requires defined objective parameters, whether change in monoclonal protein or change on imaging (Caers et al., 2018a; Rajkumar, 2024). Reporting symptomatic improvement as a symptomatic outcome, and stopping there, is the most honest way to present the data at hand.

Implications for practice and reporting

The principal lesson of this case is short: a result that does not yet exist must not be treated as a negative result. The principle is simple, its application demands documentary discipline. Medical records should note separately the findings that are positive, the findings genuinely negative after testing, and the investigations that failed or were never done together with the reason. Work on communicating diagnostic uncertainty shows structured disclosure improving patient understanding without reducing trust (Dahm et al., 2023; Rising et al., 2020), while analyses of patient and clinician experience show unstated uncertainty becoming a source of downstream error (Cox et al., 2021; Meyer et al., 2021).

For resource-constrained services, several steps return high information value for their cost. Light chain immunohistochemistry on the existing tissue block can confirm clonality without a new invasive procedure. Trephine biopsy can be offered as a procedure distinct from repeated aspiration when aspiration fails. Serum free light chain measurement supplies quantitative information that neither the gamma fraction nor urine testing replaces. Where whole-body magnetic resonance imaging or positron emission tomography is out of reach, whole-body low-dose computed tomography is far more informative than conventional radiographic survey (Hillengass et al., 2017; Nagarajan et al., 2025). Awareness among frontline clinicians of atypical myeloma presentations has also been shown to shorten time to diagnosis (Mikhael et al., 2023).

Limitations

The limitations of this report are fundamental and need stating without softening. The data are historical and retrospective, so their completeness rests entirely on what was recorded at the time. Tissue clonality confirmation is unavailable. Bone marrow aspiration was non-diagnostic and trephine biopsy was not performed. Imaging was confined to specific anatomical regions and to conventional radiographic survey. No follow-up exists after discharge, so the most important question, whether the patient progressed to multiple myeloma or kept localised disease, cannot be answered. The patient's perspective is undocumented as well. As a single case report, these findings cannot be generalised and supply no estimate of frequency or treatment effectiveness. The value lies in the diagnostic reasoning, and that reasoning helps only so far as its boundaries are stated clearly.

Conclusion

This case exposes three reflex conclusions that do not hold up during evaluation of plasma cell neoplasms. Serum protein electrophoresis without a monoclonal peak does not exclude a plasma cell disorder, and in this patient it was immunofixation that revealed a lambda light-chain monoclonal gammopathy. A bone marrow aspiration ending in dry tap yields nothing at all about plasma cell burden in the marrow, so it cannot be used to declare the marrow uninvolved. A conventional radiographic survey finding no additional lesions excludes little and does not match more sensitive whole-body examination.

On the evidence genuinely available, the most accurate diagnostic label for this patient is clavicular plasmacytoma with lambda light-chain monoclonal gammopathy and incomplete assessment of disease extent. Calling the disease solitary is not yet justified, since trephine biopsy, quantitative serum free light chain measurement, and whole-body imaging were unavailable. Excluding multiple myeloma cannot be asserted either, because the unmet criteria here come from investigations never performed rather than from negative results. The fall in pain score from 5 to 0 during admission is a symptomatic outcome and demonstrates no tumour response, since remeasurement of the mass and laboratory response parameters were unavailable.

The practical implications reach past this single case. Clinicians facing a destructive bone mass with plasma cell features should finish three steps before reaching for the solitary label: confirmation of clonality in tissue through immunohistochemistry, bone marrow assessment including trephine biopsy when aspiration fails, and whole-body imaging with the most sensitive accessible modality. In services short of equipment, whole-body low-dose computed tomography and serum free light chain measurement return the most information for what they cost. Beyond that, documentation separating negative findings from investigations never performed costs nothing, works anywhere, and protects patients from treatment decisions built on false

certainty. Further research should map diagnostic gaps in plasmacytoma across resource-constrained settings and build tiered evaluation pathways that hold when referral modalities are only partly available.

Declarations

Ethics approval and consent to publish

This case report was compiled from anonymised medical records; all direct identifiers were removed and dates are presented at the level of month and year. Written consent to publish from the patient or their legal representative, together with the number and date of institutional ethics committee approval, must be supplied by the corresponding author at submission: [Ethics committee name], [Approval number], [Approval date].

Funding

This research received no specific grant from funding agencies in the public, commercial, or not-for-profit sectors.

Conflict of interest

The authors declare no conflict of interest relating to this manuscript.

Data availability

All data underpinning the conclusions of this report are presented within the manuscript and its tables. The original medical records cannot be shared openly because they contain potentially identifying patient information; reasonable requests may be directed to the corresponding author.

Author contributions

Anak Agung Fendy Triwicaksana: conceptualisation of the report, collection and verification of clinical data, drafting of the original manuscript, and finalisation of the text. Kurrotun Ayni Bakrun: review and interpretation of the histopathology specimens, literature review, and critical revision of the manuscript for intellectual content. Both authors have read and approved the final version and accept responsibility for its content.

Use of artificial intelligence

Artificial intelligence tools were used in preparing this manuscript for structuring, language editing, and reference retrieval and verification. [CONFIRM the tool names and the scope of their use in line with the target journal's policy.] All clinical data, interpretations, and references have been checked and approved by all authors, who take full responsibility for the content of the manuscript.

Acknowledgements

[Complete if applicable; leave blank otherwise.]

REFERENCES

[1]. Alghisi, A., Borghetti, P., Maddalo, M., Roccaro, A. M., Tucci, A., Mazzola, R., Magrini, S. M., Lo Casto, A., Bonù, M. L., Tomasini, D., Pasinetti, N., Peretto, G., Bertagna, F., Tomasi, C., Buglione, M., & Triggiani, L. (2020). Radiotherapy for the treatment of solitary plasmacytoma: 7-Year outcomes by a mono-institutional experience. ***Journal of Cancer Research and Clinical Oncology***, 147(6), 1773-1779. https://doi.org/10.1007/s00432-020-03452-y

[2]. Arcila, M. E., Yu, W., Syed, M., Kim, H., Maciag, L., Yao, J., Ho, C., Petrova, K., Moung, C., Salazar, P., Rijo, I., Baldi, T., Zehir, A., Landgren, O., Park, J., Roshal, M., Dogan, A., & Nafa, K. (2019). Establishment of immunoglobulin heavy (IGH) chain clonality testing by next-generation sequencing for routine characterization of B-cell and plasma cell neoplasms. ***The Journal of Molecular Diagnostics***, 21(2), 330-342. https://doi.org/10.1016/j.jmoldx.2018.10.008

[3]. Ascione, S., Harel, S., Besson, F. L., Belkhir, R., Henry, J., Royer, B., Arnulf, B., Mariette, X., & Seror, R. (2023). Chemotherapy in solitary bone plasmacytoma to prevent evolution to multiple myeloma. Haematologica, 108(11), 3160-3164. https://doi.org/10.3324/haematol.2022.282214

[4]. Baffour, F. I., Glazebrook, K. N., Kumar, S. K., & Broski, S. M. (2020). Role of imaging in multiple myeloma. American Journal of Hematology, 95(8), 966-977. https://doi.org/10.1002/ajh.25846

[5]. Bansal, R., Rakshit, S., & Kumar, S. (2021). Extramedullary disease in multiple myeloma. ***Blood Cancer Journal***, 11(9). https://doi.org/10.1038/s41408-021-00527-y

[6]. Bladé, J., Beksac, M., Caers, J., Jurczyszyn, A., von Lilienfeld-Toal, M., Moreau, P., Rasche, L., Rosiñol, L., Usmani, S. Z., Zamagni, E., & Richardson, P. (2022). Extramedullary disease in multiple myeloma: A systematic literature review. ***Blood Cancer Journal***, 12(3). https://doi.org/10.1038/s41408-022-00643-3

[7]. Bolarinwa, A., Zanwar, S., Abdallah, N., Buadi, F. K., Hayman, S. R., Gertz, M. A., Dispenzieri, A., Muchtar, E., Kapoor, P., Gonsalves, W., Kourelis, T., Dingli, D., Warsame, R., Leung, N., Cook, J., Binder, M., Lin, Y., Hwa, Y., Rogers, M. G., . . . Kumar, S. K. (2025). Clinical characteristics, treatment responses and outcomes of light chain multiple myeloma. ***American Journal of Hematology***, 100(12), 2286-2292. https://doi.org/10.1002/ajh.70099

[8]. Caers, J., Garderet, L., Kortüm, K. M., O'Dwyer, M. E., van de Donk, N. W. C. J., Binder, M., Dold, S. M., Gay, F., Corre, J., Beguin, Y., Ludwig, H., Larocca, A., Driessen, C., Dimopoulos, M. A., Boccadoro, M., Gramatzki, M., Zweegman, S., Einsele, H., Cavo, M., . . . Engelhardt, M. (2018). European Myeloma Network recommendations on tools for the diagnosis and monitoring of multiple myeloma: What to use and when. Haematologica, 103(11), 1772-1784. https://doi.org/10.3324/haematol.2018.189159

[9]. Caers, J., Paiva, B., Zamagni, E., Leleu, X., Bladé, J., Kristinsson, S. Y., Touzeau, C., Abildgaard, N., Terpos, E., Heusschen, R., Ocio, E., Delforge, M., Sezer, O., Beksac, M., Ludwig, H., Merlini, G., Moreau, P., Zweegman, S., Engelhardt, M., & Rosiñol, L. (2018). Diagnosis, treatment, and response assessment in solitary plasmacytoma: Updated recommendations from a European expert panel. ***Journal of Hematology & Oncology***, 11(1). https://doi.org/10.1186/s13045-017-0549-1

[10]. Caponi, L., Romiti, N., Koni, E., Fiore, A. D., Paolicchi, A., & Franzini, M. (2019). Inter-assay variability in automated serum free light chain assays and their use in the clinical laboratory. Critical Reviews in Clinical Laboratory Sciences, 57(2), 73-85. https://doi.org/10.1080/10408363.2019.1670133

[11]. Chakraborty, R., Hillengass, J., & Lentzsch, S. (2023). How do we image patients with multiple myeloma and precursor states***? British Journal of Haematology***, 203(4), 536-545. https://doi.org/10.1111/bjh.18880

[12]. Chang, W. I., Koh, H. K., Yoon, S.-S., Kim, H.-S., Eom, K.-Y., & Kim, I. H. (2020). The predictive value of serum myeloma protein in solitary plasmacytoma. ***Radiation Oncology Journal***, 38(2), 129-137. https://doi.org/10.3857/roj.2019.00570

[13]. Charalampous, C., Claveau, J.-S., Kapoor, P., Binder, M., Buadi, F. K., Cook, J., Dingli, D., Dispenzieri, A., Fonder, A. L., Gertz, M. A., Gonsalves, W., Hayman, S. R., Hobbs, M. A., Hwa, Y. L., Kourelis, T., Lacy, M. Q., Leung, N., Lin, Y., Warsame, R., . . . Kumar, S. K. (2025). Solitary plasmacytoma: Single-institution experience, and systematic review and meta-analysis of clinical outcomes. Blood Advances, 9(7), 1559-1570. https://doi.org/10.1182/bloodadvances.2024013355

[14]. Corso, A., & Mangiacavalli, S. (2017). Non-secretory myeloma: Ready for a new definition? ***Mediterranean Journal of Hematology and Infectious Diseases***, 9(1), e2017053. https://doi.org/10.4084/MJHID.2017.053

[15]. Cowan, A. J., Green, D. J., Kwok, M., Lee, S., Coffey, D. G., Holmberg, L. A., Tuazon, S., Gopal, A. K., & Libby, E. N. (2022). Diagnosis and management of multiple myeloma. Jama, 327(5), 464. https://doi.org/10.1001/jama.2022.0003

[16]. Cox, C. L., Miller, B. M., Kuhn, I., & Fritz, Z. (2021). Diagnostic uncertainty in primary care: What is known about its communication, and what are the associated ethical issues? Family Practice, 38(5), 654-668. https://doi.org/10.1093/fampra/cmab023

[17]. Curry, J., O'steen, L., Morris, C. G., Kirwan, J. M., & Mendenhall, W. M. (2020). Long-term outcomes after definitive radiation therapy for solitary plasmacytoma. ***American Journal of Clinical Oncology***, 43(10), 709-713. https://doi.org/10.1097/COC.0000000000000734

[18]. Dahm, M. R., Cattanach, W., Williams, M., Basseal, J. M., Gleason, K., & Crock, C. (2022). Communication of diagnostic uncertainty in primary care and its impact on patient experience: An integrative systematic review. ***Journal of General Internal Medicine***, 38(3), 738-754. https://doi.org/10.1007/s11606-022-07768-y

[19]. Dasari, S., Kohlhagen, M. C., Dispenzieri, A., Willrich, M. A. V., Snyder, M. R., Kourelis, T. V., Lust, J. A., Mills, J. R., Kyle, R. A., & Murray, D. L. (2022). Detection of plasma cell disorders by mass spectrometry: A comprehensive review of 19,523 cases. Mayo Clinic Proceedings, 97(2), 294-307. https://doi.org/10.1016/j.mayocp.2021.07.024

[20]. Dejoie, T., Corre, J., Caillon, H., Hulin, C., Perrot, A., Caillot, D., Boyle, E., Chretien, M.-L., Fontan, J., Belhadj, K., Brechignac, S., Decaux, O., Voillat, L., Rodon, P., Fitoussi, O., Araujo, C., Benboubker, L., Fontan, C., Tiab, M., . . . Avet-Loiseau, H. (2016). Serum free light chains, not urine specimens, should be used to evaluate response in light-chain multiple myeloma. Blood, 128(25), 2941-2948. https://doi.org/10.1182/blood-2016-07-726778

[21]. Dimopoulos, M. A., Moreau, P., Terpos, E., Mateos, M. V., Zweegman, S., Cook, G., Delforge, M., Hájek, R., Schjesvold, F., Cavo, M., Goldschmidt, H., Facon, T., Einsele, H., Boccadoro, M., San-Miguel, J., Sonneveld, P.,

& Mey, U. (2021). Multiple myeloma: Eha-esmo clinical practice guidelines for diagnosis, treatment and follow-up†. Annals of Oncology, 32(3), 309-322. https://doi.org/10.1016/j.annonc.2020.11.014

[22]. Dimopoulos, M. A., Terpos, E., Boccadoro, M., Moreau, P., Mateos, M.-V., Zweegman, S., Cook, G., Engelhardt, M., Delforge, M., Hajek, R., Schjesvold, F., Gay, F., Manier, S., Weisel, K. C., Kaiser, M., van de Donk, N. W. C. J., Zamagni, E., Rodriguez-Otero, P., Perrot, A., . . . Sonneveld, P. (2025). Eha–emn evidence-based guidelines for diagnosis, treatment and follow-up of patients with multiple myeloma. Nature Reviews Clinical Oncology, 22(9), 680-700. https://doi.org/10.1038/s41571-025-01041-x

[23]. Elsayad, K., Oertel, M., König, L., Hüske, S., Le Ray, E., Meheissen, M. A. M., Elsaid, A. A., Elfaham, E., Debus, J., Kirova, Y., Herfarth, K., & Eich, H. T. (2020). Maximizing the clinical benefit of radiotherapy in solitary plasmacytoma: An international multicenter analysis. Cancers, 12(3), 676. https://doi.org/10.3390/cancers12030676

[24]. Fend, F., Dogan, A., & Cook, J. R. (2022). Plasma cell neoplasms and related entities—evolution in diagnosis and classification. Virchows Archiv, 482(1), 163-177. https://doi.org/10.1007/s00428-022-03431-3

[25]. Fleming, C. K. A., Swarttouw, T., de Kat Angelino, C. M., Jacobs, J. F. M., & Russcher, H. (2019). Method comparison of four clinically available assays for serum free light chain analysis. Clinical Chemistry and Laboratory Medicine (CCLM), 58(1), 85-94. https://doi.org/10.1515/cclm-2019-0533

[26]. Gagnier, J. J., Kienle, G., Altman, D. G., Moher, D., Sox, H., & Riley, D. (2014). The CARE guidelines: Consensus-based clinical case report guideline development. ***Journal of Clinical Epidemiology***, 67(1), 46-51. https://doi.org/10.1016/j.jclinepi.2013.08.003

[27]. Gantana, E. J., Musekwa, E., & Chapanduka, Z. C. (2024). Advances in estimating plasma cells in bone marrow: A comprehensive method review. ***African Journal of Laboratory Medicine***, 13(1). https://doi.org/10.4102/ajlm.v13i1.2381

[28]. Ganzel, C., Trestman, S., Levi, S., Gatt, M. E., Lavi, N., Vaxman, I., Rouvio, O., Magen, H., Lebel, E., Horowitz, N. A., Leiba, M., Tadmor, T., Herzog Tzarfati, K., Surio, C., Yeganeh, S., Dally, N., Avivi, I., & Cohen, Y. C. (2022). Clinical features, therapy patterns, outcomes and prognostic factors of solitary plasmacytomas: A report of the Israeli Myeloma Study Group. Leukemia & Lymphoma, 63(14), 3448-3455. https://doi.org/10.1080/10428194.2022.2118535

[29]. Hatipoğlu, U., Seyhan, M., Ulas, T., Dal, M. S., & Altuntaş, F. (2025). Solitary plasmacytomas: Current status in 2025. Hematology Reports, 17(4), 32. https://doi.org/10.3390/hematolrep17040032

[30]. Heaney, J. L. J., Campbell, J. P., Griffin, A. E., Birtwistle, J., Shemar, M., Child, J. A., Gregory, W. M., Cairns, D. A., Morgan, G., Jackson, G., & Drayson, M. T. (2017). Diagnosis and monitoring for light chain only and oligosecretory myeloma using serum free light chain tests. ***British Journal of Haematology***, 178(2), 220-230. https://doi.org/10.1111/bjh.14753

[31]. Hillengass, J., Moulopoulos, L. A., Delorme, S., Koutoulidis, V., Mosebach, J., Hielscher, T., Drake, M., Rajkumar, S. V., Oestergaard, B., Abildgaard, N., Hinge, M., Plesner, T., Suehara, Y., Matsue, K., Withofs, N., Caers, J., Waage, A., Goldschmidt, H., Dimopoulos, M. A., . . . Terpos, E. (2017). Whole-body computed tomography versus conventional skeletal survey in patients with multiple myeloma: A study of the International Myeloma Working Group. Blood Cancer Journal, 7(8), e599-e599. https://doi.org/10.1038/bcj.2017.78

[32]. Hillengass, J., Usmani, S., Rajkumar, S. V., Durie, B. G. M., Mateos, M.-V., Lonial, S., Joao, C., Anderson, K. C., García-Sanz, R., Riva, E., Du, J., van de Donk, N., Berdeja, J. G., Terpos, E., Zamagni, E., Kyle, R. A., San Miguel, J., Goldschmidt, H., Giralt, S., . . . Lentzsch, S. (2019). International Myeloma Working Group consensus recommendations on imaging in monoclonal plasma cell disorders. The Lancet Oncology, 20(6), e302-e312. https://doi.org/10.1016/S1470-2045(19)30309-2

[33]. Huang, J., Chan, S. C., Lok, V., Zhang, L., Lucero-Prisno, D. E., Xu, W., Zheng, Z.-J., Elcarte, E., Withers, M., & Wong, M. C. S. (2022). The epidemiological landscape of multiple myeloma: A global cancer registry estimate of disease burden, risk factors, and temporal trends. The Lancet Haematology, 9(9), e670-e677. https://doi.org/10.1016/S2352-3026(22)00165-X

[34]. Humphries, J. E. (1990). Dry tap bone marrow aspiration: Clinical significance. ***American Journal of Hematology,*** 35(4), 247-250. https://doi.org/10.1002/ajh.2830350405

[35]. Jacobs, J. F. M., Turner, K. A., Graziani, M. S., Frinack, J. L., Ettore, M. W., Tate, J. R., Booth, R. A., McCudden, C. R., Keren, D. F., Delgado, J. C., Zemtsovskaja, G., Fullinfaw, R. O., Caldini, A., de Malmanche, T., Katakouzinos, K., Burke, M., Palladini, G., Altinier, S., Zaninotto, M., . . . Willrich, M. A. V. (2020). An international multi-center serum protein electrophoresis accuracy and M-protein isotyping study. Part II: Limit of detection and follow-up of patients with small M-proteins. Clinical Chemistry and Laboratory Medicine (CCLM), 58(4), 547-559. https://doi.org/10.1515/cclm-2019-1105

[36]. Jin, Y., Savage, N. M., Bollag, R. J., Xu, H., & Singh, G. (2021). Light chain multiple myeloma: High serum free light chain concentrations portend renal damage and poorer survival. ***The Journal of Applied Laboratory Medicine***, 6(6), 1592-1600. https://doi.org/10.1093/jalm/jfab090

[37]. Katodritou, E., Kastritis, E., Dalampira, D., Kanellias, N., Labropoulou, V., Kyriakidis, G., Douka, V., Delimpasi, S., Stoumbos, D., Spanoudakis, E., Papageorgiou, S., Fotiou, D., Gkioka, A., Triantafyllou, T., Ntanasis-Stathopoulos, I., Papadopoulou, T., Tsirou, K., Sevastoudi, A., Daiou, A., . . . Dimopoulos, M. (2025). Characteristics and survival outcomes of solitary plasmacytomas: A 30-year experience of the Greek Myeloma Study Group on 175 patients. ***American Journal of Hematology***, 100(8), 1334-1342. https://doi.org/10.1002/ajh.27725

[38]. Kawahara, Y., Kinoshita, M., Ohata, K., Tamai, S., Miyashita, K., & Nakada, M. (2023). Rapid conversion from solitary plasmacytoma with minimal skull marrow involvement to symptomatic multiple myeloma: A case report. SN Comprehensive Clinical Medicine, 5(1). https://doi.org/10.1007/s42399-023-01388-1

[39]. Khurana, R., Zaheer, S., & Ahuja, S. (2025). Solitary extramedullary plasmacytoma in the hilar region: A case of minimal marrow involvement in an elderly male. ***International Journal of Surgery Case Reports***, 126(C). https://doi.org/10.1016/j.ijscr.2024.110795

[40]. Kumar, S. K., Callander, N. S., Adekola, K., Anderson, L., Baljevic, M., Campagnaro, E., Castillo, J. J., Chandler, J. C., Costello, C., Efebera, Y., Faiman, M., Garfall, A., Godby, K., Hillengass, J., Holmberg, L., Htut, M., Huff, C. A., Kang, Y., Hultcrantz, M., . . . Kumar, R. (2020). Multiple myeloma, version 3.2021, NCCN clinical practice guidelines in oncology. ***Journal of the National Comprehensive Cancer Network***, 18(12), 1685-1717. https://doi.org/10.6004/JNCCN.2020.0057

[41]. Lai, A. Y. T., Riddell, A., Barwick, T., Boyd, K., Rockall, A., Kaiser, M., Koh, D.-M., Saffar, H., Yusuf, S., & Messiou, C. (2019). Interobserver agreement of whole-body magnetic resonance imaging is superior to whole-body computed tomography for assessing disease burden in patients with multiple myeloma. European Radiology, 30(1), 320-327. https://doi.org/10.1007/s00330-019-06281-x

[42]. Li, Y., Zheng, G., Liu, T., Liang, Y., Huang, J., Liu, X., Huang, J., Cheng, Z., Lu, S., & Huang, L. (2020). Surgical resection of solitary bone plasmacytoma of atlas and reconstruction with 3-dimensional−printed titanium patient-specific implant. World Neurosurgery, 139, 322-329. https://doi.org/10.1016/j.wneu.2020.04.041

[43]. Lim, K. J. C., Steinhardt, M., Rees, M. J., Greipp, P., Kelemen, K., Dispenzieri, A., Jevremovic, D., Baughn, L., Buadi, F. K., Dingli, D., Hayman, S. R., Kapoor, P., Muchtar, E., Leung, N., Fonder, A., Hobbs, M., Hwa, Y. L., Warsame, R., Kourelis, T. V., . . . Yadav, U. (2026). A multicenter study of progression risk and outcomes in solitary bone plasmacytoma with and without marrow involvement. Blood Advances, 10(12), 4286-4295. https://doi.org/10.1182/bloodadvances.2025019136

[44]. Long, T. E., Indridason, O. S., Palsson, R., Rognvaldsson, S., Love, T. J., Thorsteinsdottir, S., Sverrisdottir, I. S., Vidarsson, B., Onundarson, P. T., Agnarsson, B. A., Sigurdardottir, M., Thorsteinsdottir, I., Olafsson, I., Thordardottir, A. R., Eythorsson, E., Jonsson, A., Gislason, G., Olafsson, A., Steingrimsdottir, H., . . . Kristinsson, S. Y. (2022). Defining new reference intervals for serum free light chains in individuals with chronic kidney disease: Results of the istopmm study. ***Blood Cancer Journal***, 12(9). https://doi.org/10.1038/s41408-022-00732-3

[45]. Lyubimova, N. V., Timofeev, Y. S., Abaev, V. M., Votyakova, O. M., & Kushlinskii, N. E. (2018). Immunochemical diagnosis of multiple myeloma. Bulletin of Experimental Biology and Medicine, 165(1), 84-87. https://doi.org/10.1007/s10517-018-4105-y

[46]. Mafra, A., Laversanne, M., Marcos-Gragera, R., Chaves, H. V. S., Mcshane, C., Bray, F., & Znaor, A. (2024). The global multiple myeloma incidence and mortality burden in 2022 and predictions for 2045**.** ***JNCI: Journal of the National Cancer Institute***, 117(5), 907-914. https://doi.org/10.1093/jnci/djae321

[47]. Malard, F., Neri, P., Bahlis, N. J., Terpos, E., Moukalled, N., Hungria, V. T. M., Manier, S., & Mohty, M. (2024). Multiple myeloma. Nature Reviews Disease Primers, 10(1). https://doi.org/10.1038/s41572-024-00529-7

[48]. Matsuoka, R., Sakamoto, N., Kato, T., Chiba, S., & Noguchi, M. (2021). A case of solitary plasmacytoma of bone showing co-expression of both immunoglobulin light chains. ***European Journal of Medical Research***, 26(1). https://doi.org/10.1186/s40001-021-00621-8

[49]. Mauro, G. P., Neffá, P. P., Villar, R. C., Martinez, G. A., & de Andrade Carvalho, H. (2021). Safety and feasibility analysis of a prospective trial on stereotactic body radiotherapy for solitary bone plasmacytoma. Acta Haematologica, 144(6), 627-632. https://doi.org/10.1159/000516570

[50]. Mena, E., Turkbey, E. B., & Lindenberg, L. (2022). Modern radiographic imaging in multiple myeloma, what is the minimum requirement? Seminars in Oncology, 49(1), 86-93. https://doi.org/10.1053/j.seminoncol.2022.01.007

[51]. Messiou, C., Porta, N., Sharma, B., Levine, D., Koh, D.-M., Boyd, K., Pawlyn, C., Riddell, A., Downey, K., Croft, J., Morgan, V., Stern, S., Cheung, B., Kyriakou, C., Kaczmarek, P., Winfield, J., Blackledge, M., Oyen, W. J. G., & Kaiser, M. F. (2021). Prospective evaluation of whole-body MRI versus FDG PET/CT for lesion detection in participants with myeloma. Radiology: Imaging Cancer, 3(5), e210048. https://doi.org/10.1148/rycan.2021210048

[52]. Meyer, A. N. D., Giardina, T. D., Khawaja, L., & Singh, H. (2021). Patient and clinician experiences of uncertainty in the diagnostic process: Current understanding and future directions. Patient Education and Counseling, 104(11), 2606-2615. https://doi.org/10.1016/j.pec.2021.07.028

[53]. Mheidly, K., Lamy De La Chapelle, T., Hunault, M., Benboubker, L., Benchalal, M., Moreau, P., Baugier de Materre, A., Decaux, O., & Laribi, K. (2019). New insights in the treatment of patients with solitary bone plasmacytoma. Leukemia & Lymphoma, 60(11), 2810-2813. https://doi.org/10.1080/10428194.2019.1605067

[54]. Migkou, M., Avivi, I., Gavriatopoulou, M., Cohen, Y. C., Fotiou, D., Kanellias, N., Ziogas, D., Eleutherakis-Papaiakovou, E., Terpos, E., Roussou, M., Kastritis, E., & Dimopoulos, M. A. (2020). Clinical characteristics and outcomes of oligosecretory and non-secretory multiple myeloma. Annals of Hematology, 99(6), 1251-1255. https://doi.org/10.1007/s00277-020-03984-w

[55]. Mignot, F., Schernberg, A., Arsène-Henry, A., Vignon, M., Bouscary, D., & Kirova, Y. (2020). Solitary plasmacytoma treated by lenalidomide-dexamethasone in combination with radiation therapy: Clinical outcomes. ***International Journal of Radiation Oncology*Biology*Physics***, 106(3), 589-596. https://doi.org/10.1016/j.ijrobp.2019.10.043

[56]. Mikhael, J., Bhutani, M., & Cole, C. E. (2023). Multiple myeloma for the primary care provider: A practical review to promote earlier diagnosis among diverse populations. ***The American Journal of Medicine***, 136(1), 33-41. https://doi.org/10.1016/j.amjmed.2022.08.030

[57]. Murray, D. L., Puig, N., Kristinsson, S., Usmani, S. Z., Dispenzieri, A., Bianchi, G., Kumar, S., Chng, W. J., Hajek, R., Paiva, B., Waage, A., Rajkumar, S. V., & Durie, B. (2021). Mass spectrometry for the evaluation of monoclonal proteins in multiple myeloma and related disorders: An International Myeloma Working Group mass spectrometry committee report. ***Blood Cancer Journal***, 11(2). https://doi.org/10.1038/s41408-021-00408-4

[58]. Nagarajan, C., Anthony, N. F., Hillengass, J., Kim, S. J., Kunacheewa, C., Datukan, J. T., Gan, G. G., Binh, V. T. T., Chim, J., Huang, J. S. Y., Chen, W., Kim, K., Rajkumar, S. V., Durie, B. G. M., Chng, W. J., & Abe, M. (2025). Imaging in plasma cell disorders—consensus recommendations of the Asian Myeloma Network bone imaging workgroup. The Lancet Regional Health - Western Pacific, 59, 101597. https://doi.org/10.1016/j.lanwpc.2025.101597

[59]. Nakaya, A., Tanaka, H., Yagi, H., Ohta, K., Shibayama, H., Kohara, T., Kanda, J., Shindo, M., Shimura, Y., Kosugi, S., Kida, T., Kaneko, H., Imada, K., Karasuno, T., Matsuda, M., Iida, M., Adachi, Y., Fuchida, S.-I., Uoshima, N., . . . Investigators, K. M. F. (2020). Retrospective analysis of plasmacytoma in Kansai Myeloma Forum registry. ***International Journal of Hematology***, 112(5), 666-673. https://doi.org/10.1007/s12185-020-02961-3

[60]. Nandakumar, B., Kumar, S. K., Dispenzieri, A., Buadi, F. K., Dingli, D., Lacy, M. Q., Hayman, S. R., Kapoor, P., Leung, N., Fonder, A., Hobbs, M., Hwa, Y. L., Muchtar, E., Warsame, R., Kourelis, T. V., Russell, S., Lust, J. A., Lin, Y., Go, R. S., . . . Gonsalves, W. I. (2020). Cytogenetic features and clinical outcomes of patients with non-secretory multiple myeloma in the era of novel agent induction therapy. Clinical Lymphoma Myeloma and Leukemia, 20(1), 53-56. https://doi.org/10.1016/j.clml.2019.09.624

[61]. Ormond Filho, A. G., Carneiro, B. C., Pastore, D., Silva, I. P., Yamashita, S. R., Consolo, F. D., Hungria, V. T. M., Sandes, A. F., Rizzatti, E. G., & Nico, M. A. C. (2019). Whole-body imaging of multiple myeloma: Diagnostic criteria. RadioGraphics, 39(4), 1077-1097. https://doi.org/10.1148/rg.2019180096

[62]. Ozkalemkas, F., Ali, R., Ozkocaman, V., Ozcelik, T., Ozan, U., Ozturk, H., Kurt, E., Evrensel, T., Yerci, O., & Tunali, A. (2005). The bone marrow aspirate and biopsy in the diagnosis of unsuspected nonhematologic malignancy: A clinical study of 19 cases. BMC Cancer, 5(1). https://doi.org/10.1186/1471-2407-5-144

[63]. Paiva, B., Puig, N., Cedena, M.-T., Rosiñol, L., Cordón, L., Vidriales, M.-B., Burgos, L., Flores-Montero, J., Sanoja-Flores, L., Lopez-Anglada, L., Maldonado, R., de la Cruz, J., Gutierrez, N. C., Calasanz, M.-J., Martin-Ramos, M.-L., Garcia-Sanz, R., Martinez-Lopez, J., Oriol, A., Blanchard, M.-J., . . . Group, O. B. O. T. G. (. E. D. M. (. P. E. E. D. L. T. E. H. M. C. S. (2020). Measurable residual disease by next-generation flow cytometry in multiple myeloma. ***Journal of Clinical Oncology***, 38(8), 784-792. https://doi.org/10.1200/JCO.19.01231

[64]. Pham, A., & Mahindra, A. (2019). Solitary plasmacytoma: A review of diagnosis and management. Current Hematologic Malignancy Reports, 14(2), 63-69. https://doi.org/10.1007/s11899-019-00499-8

[65]. Rajkumar, S. V. (2022). Multiple myeloma: 2022 Update on diagnosis, risk stratification, and management. **American Journal of Hematology**, 97(8), 1086-1107. https://doi.org/10.1002/ajh.26590

[66]. Rajkumar, S. V. (2024). Multiple myeloma: 2024 Update on diagnosis, risk-stratification, and management. ***American Journal of Hematology***, 99(9), 1802-1824. https://doi.org/10.1002/ajh.27422

[67]. Rajkumar, S. V., & Kumar, S. (2025). Monoclonal gammopathy of undetermined significance. ***New England Journal of Medicine***, 393(13), 1315-1326. https://doi.org/10.1056/NEJMra2412716

[68]. Rajkumar, S. V., Dimopoulos, M. A., Palumbo, A., Blade, J., Merlini, G., Mateos, M.-V., Kumar, S., Hillengass, J., Kastritis, E., Richardson, P., Landgren, O., Paiva, B., Dispenzieri, A., Weiss, B., LeLeu, X., Zweegman, S., Lonial, S., Rosinol, L., Zamagni, E., . . . Miguel, J. F. S. (2014). International Myeloma Working Group updated criteria for the diagnosis of multiple myeloma. The Lancet Oncology, 15(12), e538-e548. https://doi.org/10.1016/S1470-2045(14)70442-5

[69]. Rasch, S., Lund, T., Asmussen, J. T., Lerberg Nielsen, A., Faebo Larsen, R., Østerheden Andersen, M., & Abildgaard, N. (2020). Multiple myeloma associated bone disease. Cancers, 12(8), 2113. https://doi.org/10.3390/cancers12082113

[70]. Riley, D. S., Barber, M. S., Kienle, G. S., Aronson, J. K., von Schoen-Angerer, T., Tugwell, P., Kiene, H., Helfand, M., Altman, D. G., Sox, H., Werthmann, P. G., Moher, D., Rison, R. A., Shamseer, L., Koch, C. A., Sun, G. H., Hanaway, P., Sudak, N. L., Kaszkin-Bettag, M., . . . Gagnier, J. J. (2017). CARE guidelines for case reports: Explanation and elaboration document. ***Journal of Clinical Epidemiology***, 89, 218-235. https://doi.org/10.1016/j.jclinepi.2017.04.026

[71]. Rising, K. L., Powell, R. E., Cameron, K. A., Salzman, D. H., Papanagnou, D., Doty, A. M. B., Latimer, L., Piserchia, K., McGaghie, W. C., & McCarthy, D. M. (2020). Development of the uncertainty communication checklist: A patient-centered approach to patient discharge from the emergency department. Academic Medicine, 95(7), 1026-1034. https://doi.org/10.1097/ACM.0000000000003231

[72]. Rodríguez-Laval, V., Lumbreras-Fernández, B., Aguado-Bueno, B., & Gómez-León, N. (2024). Imaging of multiple myeloma: Present and future. ***Journal of Clinical Medicine***, 13(1), 264. https://doi.org/10.3390/jcm13010264

[73]. Rosiñol, L., Beksac, M., Zamagni, E., Van de Donk, N. W. C. J., Anderson, K. C., Badros, A., Caers, J., Cavo, M., Dimopoulos, M., Dispenzieri, A., Einsele, H., Engelhardt, M., Fernández de Larrea, C., Gahrton, G., Gay, F., Hájek, R., Hungria, V., Jurczyszyn, A., Kröger, N., . . . Bladé, J. (2021). Expert review on soft-tissue plasmacytomas in multiple myeloma: Definition, disease assessment and treatment considerations. ***British Journal of Haematology***, 194(3), 496-507. https://doi.org/10.1111/bjh.17338

[74]. Schieferdecker, A., Hörber, S., Ums, M., Besemer, B., Bokemeyer, C., Peter, A., & Weisel, K. (2020). Comparison of three different serum-free light-chain assays—implications on diagnostic and therapeutic monitoring of multiple myeloma***. Blood Cancer Journal,*** 10(1). https://doi.org/10.1038/s41408-019-0267-8

[75]. Shen, X., Liu, S., Wu, C., Wang, J., Li, J., & Chen, L. (2020). Survival trends and prognostic factors in patients with solitary plasmacytoma of bone: A population-based study. Cancer Medicine, 10(2), 462-470. https://doi.org/10.1002/cam4.3533

[76]. Simeone, F. J., Harvey, J. P., Yee, A. J., O'Donnell, E. K., Raje, N. S., Torriani, M., & Bredella, M. A. (2018). Value of low-dose whole-body CT in the management of patients with multiple myeloma and precursor states. Skeletal Radiology, 48(5), 773-779. https://doi.org/10.1007/s00256-018-3066-6

[77]. Singh, G. (2020). Serum and urine protein electrophoresis and serum-free light chain assays in the diagnosis and monitoring of monoclonal gammopathies. ***The Journal of Applied Laboratory Medicine***, 5(6), 1358-1371. https://doi.org/10.1093/jalm/jfaa153

[78]. Sun, H., Liu, A., Liu, L., Wang, W., Cai, Z., Yan, H., Chen, L., Gao, G., Wang, F., Liao, A., Chen, B., Feng, J., Li, J., Huang, D.-P., Gao, D., Zhang, Q.-K., Luo, J., Fu, R., Du, J., & Lu, J. (2023). Outcome and characteristics of nonsecretory multiple myeloma compared with secretory multiple myeloma: A retrospective multicenter study from China. BMC Cancer, 23(1). https://doi.org/10.1186/s12885-023-11223-4

[79]. Suryavanshi, H., Patankar, S., Dhumal, S., & Choudhari, S. (2021). Solitary plasmacytoma of jaw bone. ***Journal of Oral and Maxillofacial Pathology***, 25(1), 205. https://doi.org/10.4103/jomfp.JOMFP_251_20

[80]. Tan, H., Gu, J., Xu, L., & Sun, G. (2021). Solitary bone plasmacytoma of spine with involvement of adjacent disc space. Medicine, 100(37), e27288. https://doi.org/10.1097/MD.0000000000027288

[81]. Terpos, E., Zamagni, E., Lentzsch, S., Drake, M. T., García-Sanz, R., Abildgaard, N., Ntanasis-Stathopoulos, I., Schjesvold, F., de la Rubia, J., Kyriakou, C., Hillengass, J., Zweegman, S., Cavo, M., Moreau, P., San-Miguel, J., Dimopoulos, M. A., Munshi, N., Durie, B. G. M., & Raje, N. (2021). Treatment of multiple myeloma-related bone disease: Recommendations from the Bone Working Group of the International Myeloma Working Group. The Lancet Oncology, 22(3), e119-e130. https://doi.org/10.1016/S1470-2045(20)30559-3

[82]. Tsang, R. W., Campbell, B. A., Goda, J. S., Kelsey, C. R., Kirova, Y. M., Parikh, R. R., Ng, A. K., Ricardi, U., Suh, C.-O., Mauch, P. M., Specht, L., & Yahalom, J. (2018). Radiation therapy for solitary plasmacytoma and multiple myeloma: Guidelines from the International Lymphoma Radiation Oncology Group. ***International Journal of Radiation Oncology*Biology*Physics***, 101(4), 794-808. https://doi.org/10.1016/j.ijrobp.2018.05.009

[83]. Turner, K. A., Frinack, J. L., Ettore, M. W., Tate, J. R., Graziani, M. S., Jacobs, J. F. M., Booth, R. A., McCudden, C. R., Keren, D. F., Delgado, J. C., Zemtsovskaja, G., Fullinfaw, R. O., Caldini, A., de Malmanche, T., Katakouzinos, K., Burke, M., Palladini, G., Altinier, S., Zaninotto, M., . . . Willrich, M. A. V. (2020). An international multi-center serum protein electrophoresis accuracy and M-protein isotyping study. Part I: Factors impacting limit of quantitation of serum protein electrophoresis. Clinical Chemistry and Laboratory Medicine (CCLM), 58(4), 533-546. https://doi.org/10.1515/cclm-2019-1104

[84]. van de Donk, N. W. C. J., Pawlyn, C., & Yong, K. L. (2021). Multiple myeloma. The Lancet, 397(10272), 410-427. https://doi.org/10.1016/S0140-6736(21)00135-5

[85]. Wu, F., Bernard, S., Fayad, L. M., Ilaslan, H., Messiou, C., Moulopoulos, L. A., & Mulligan, M. E. (2021). Updates and ongoing challenges in imaging of multiple myeloma: <I>AJR</i> expert panel narrative review. ***American Journal of Roentgenology***, 217(4), 775-785. https://doi.org/10.2214/AJR.21.25878

[86]. Yadav, U., Kumar, S. K., Baughn, L. B., Dispenzieri, A., Greipp, P., Ketterling, R., Jevremovic, D., Buadi, F. K., Dingli, D., Lacy, M. Q., Fonseca, R., Bergsagel, P. L., Ailawadhi, S., Roy, V., Parrondo, R., Sher, T., Hayman, S. R., Kapoor, P., Leung, N., . . . Gonsalves, W. I. (2023). Impact of cytogenetic abnormalities on the risk of disease progression in solitary bone plasmacytomas. Blood, 142(22), 1871-1878. https://doi.org/10.1182/blood.2023021187

[87]. Yang, X.-W., Zhou, G.-C., Long, Z.-S., Gong, F.-P., & Chen, G. (2023). Solitary bone plasmacytoma of the tibia presenting as chronic osteomyelitis: A rare case report and literature review. Medicine, 102(12), e33307. https://doi.org/10.1097/MD.0000000000033307

[88]. Zamagni, E., Tacchetti, P., & Cavo, M. (2019). Imaging in multiple myeloma: How? When? Blood, 133(7), 644-651. https://doi.org/10.1182/blood-2018-08-825356

[89]. Zhang, N., Wu, J., Wang, Q., Liang, Y., Li, X., Chen, G., Ma, L., Liu, X., & Zhou, F. (2023). Global burden of hematologic malignancies and evolution patterns over the past 30 years. ***Blood Cancer Journal***, 13(1). https://doi.org/10.1038/s41408-023-00853-3

[90]. Óskarsson, J. Þ., Rögnvaldsson, S., Thorsteinsdottir, S., Long, T. E., Ólafsson, A., Eythorsson, E., Jónsson, Á., Viðarsson, B., Önundarson, P. T., Agnarsson, B. A., Pálmason, R., Sigurðardóttir, M., Þorsteinsdóttir, I., Ólafsson, Í., Harding, S. J., Durie, B. G. M., Love, T. J., & Kristinsson, S. Y. (2024). The significance of free light-chain ratio in light-chain monoclonal gammopathy of undetermined significance: A flow cytometry sub-study of the istopmm screening study. ***Blood Cancer Journal***, 14(1). https://doi.org/10.1038/s41408-024-01201-9